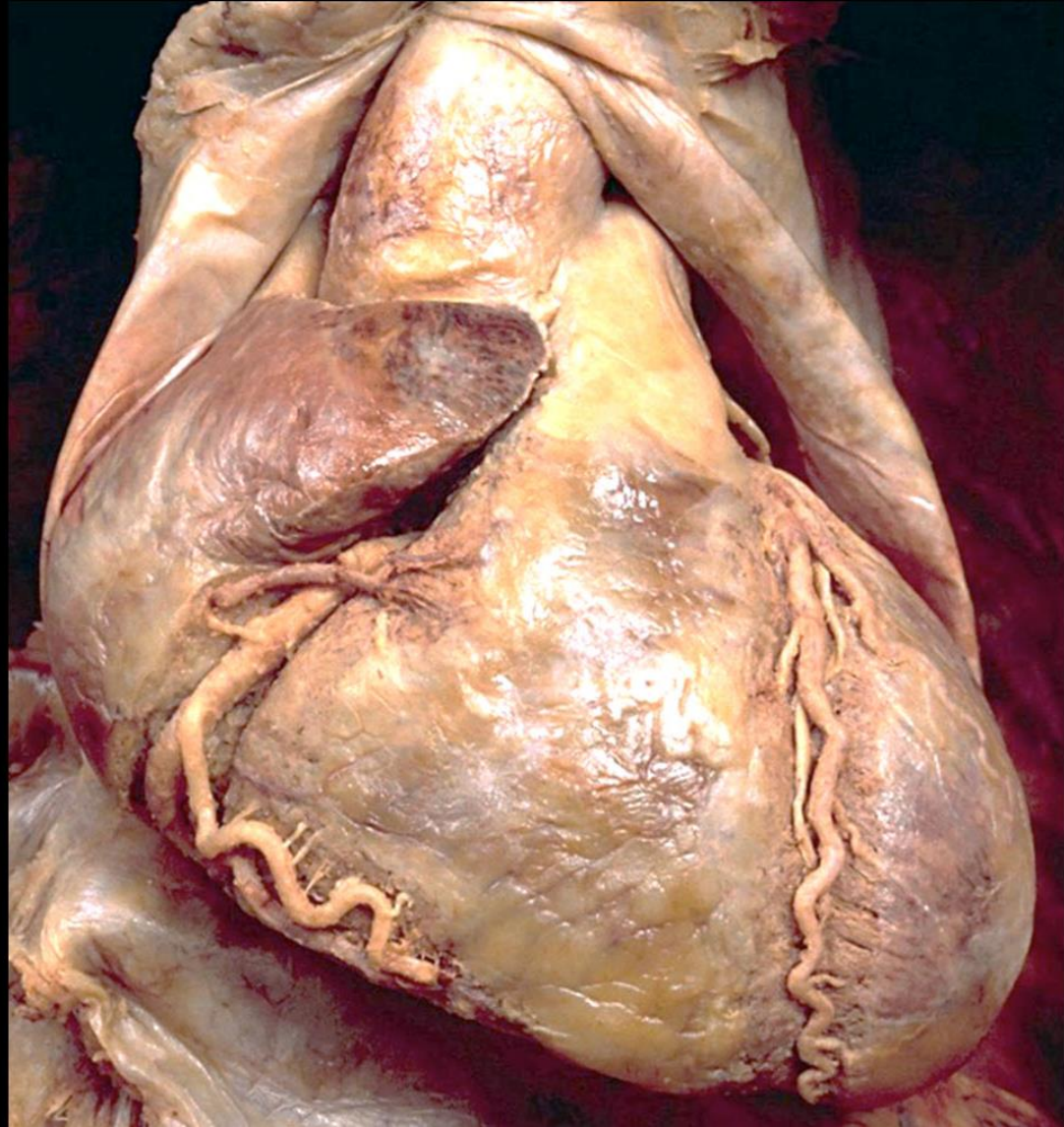
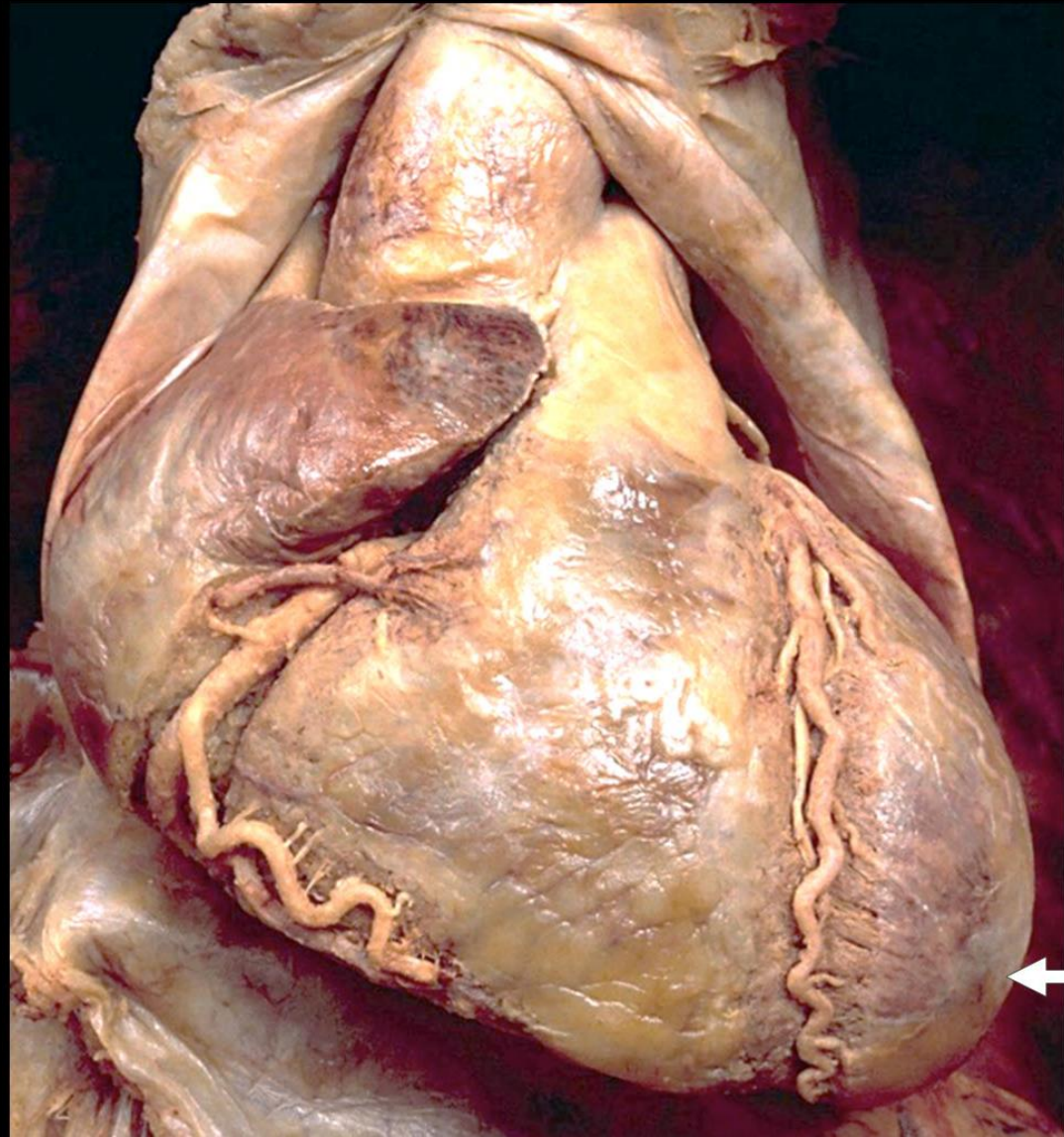


Cardiovascular system & Mediastinum

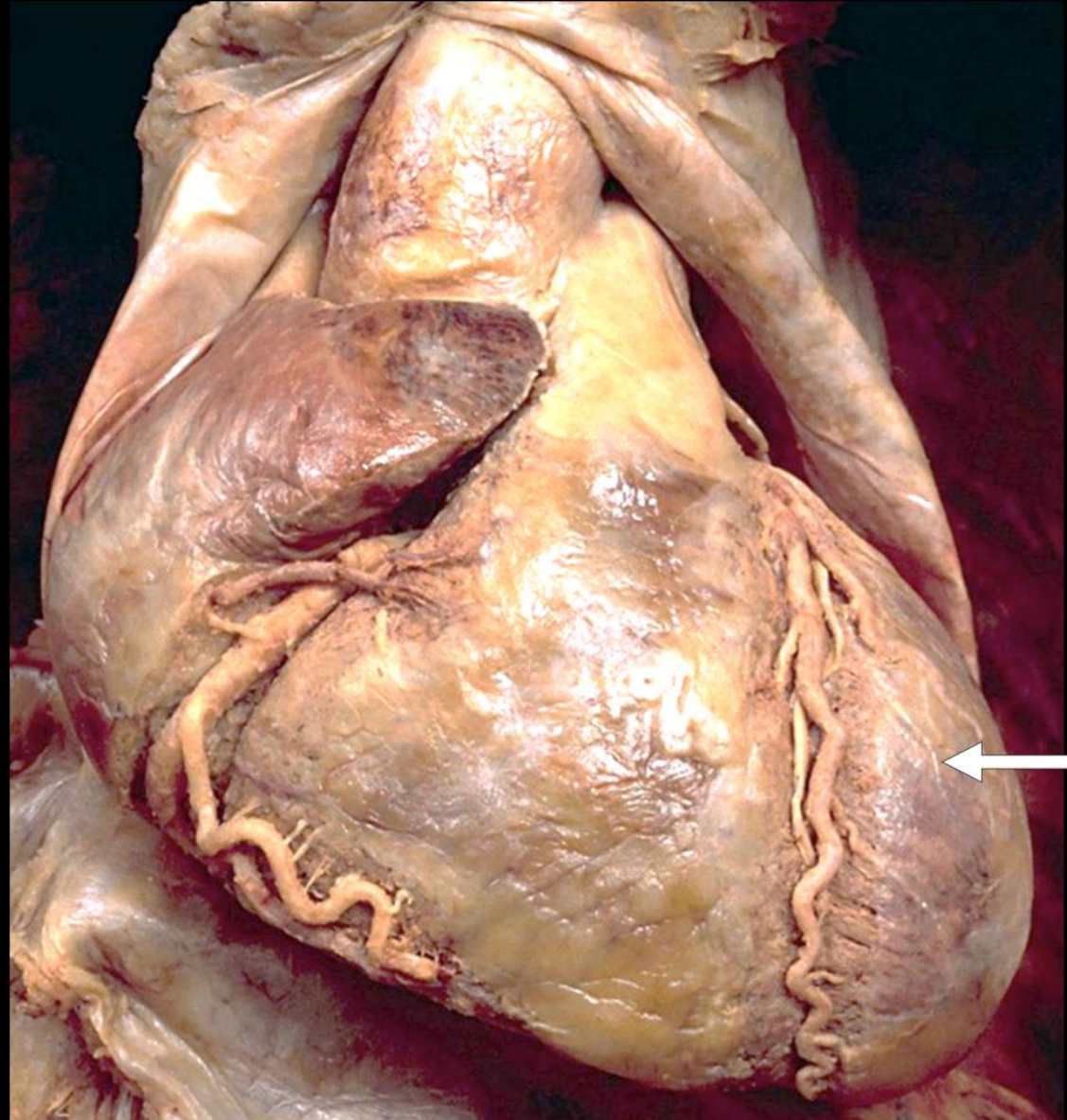
Sternocostal surface



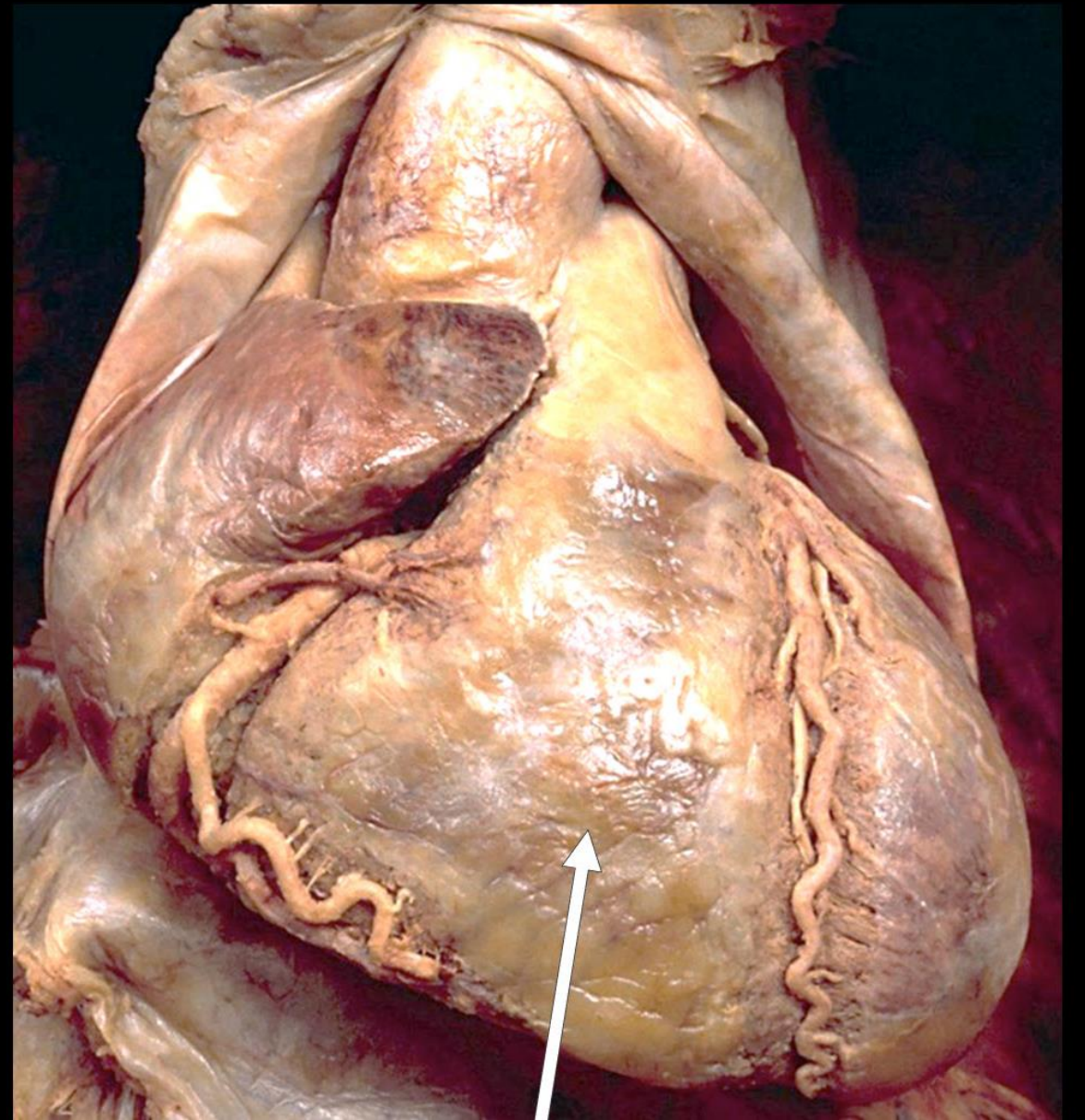
Apex of heart



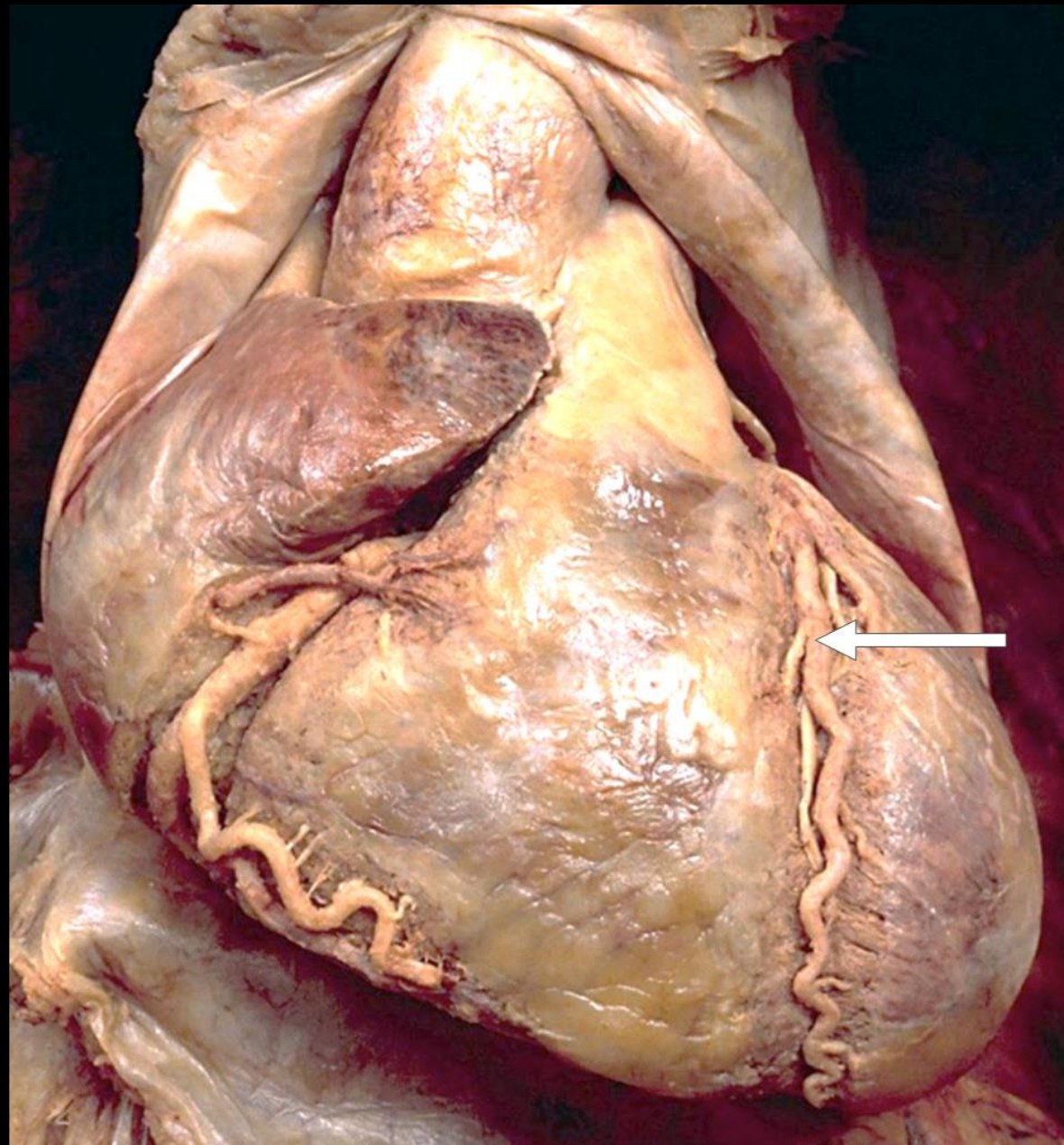
Left ventricle



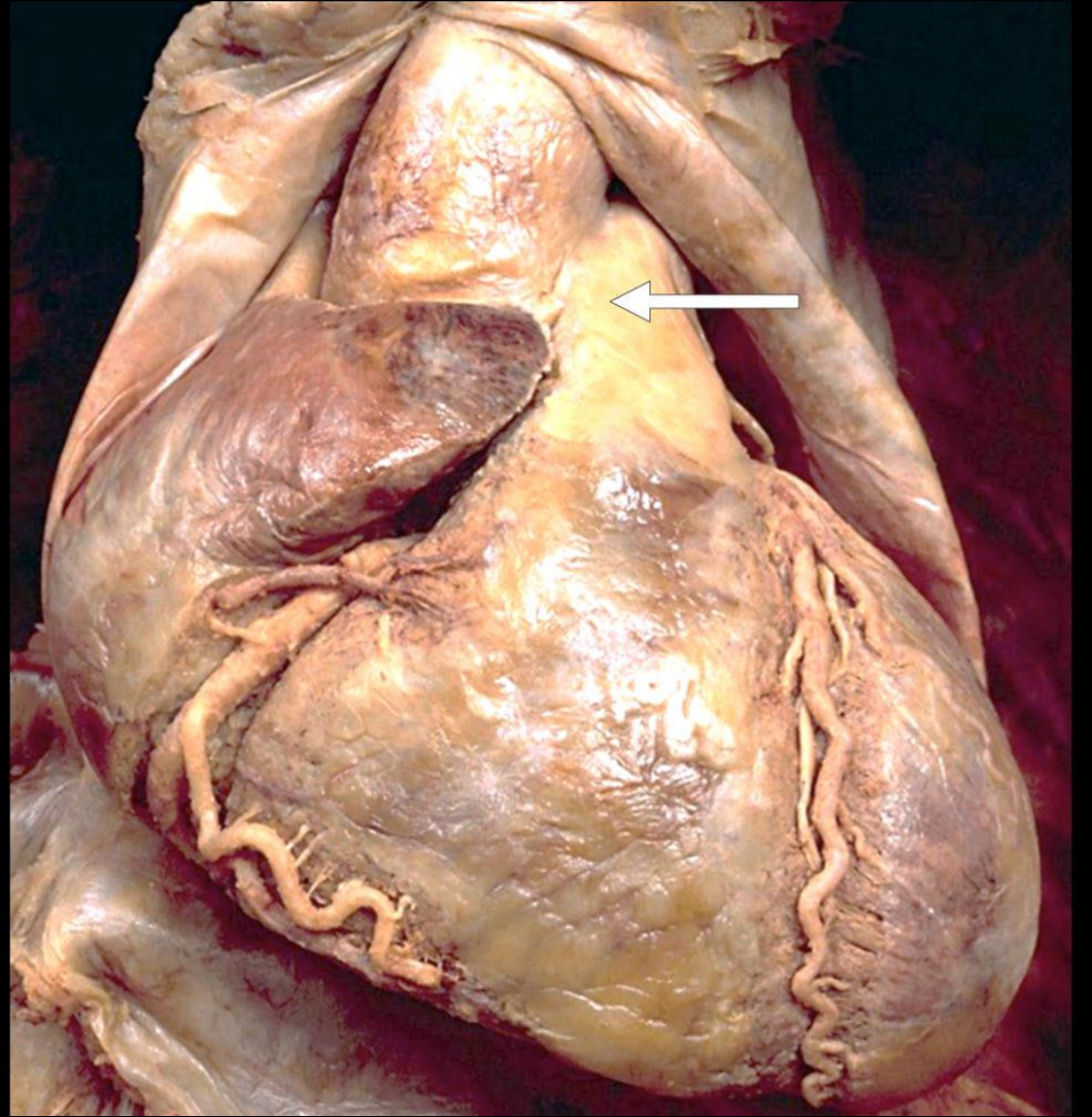
Right ventricle



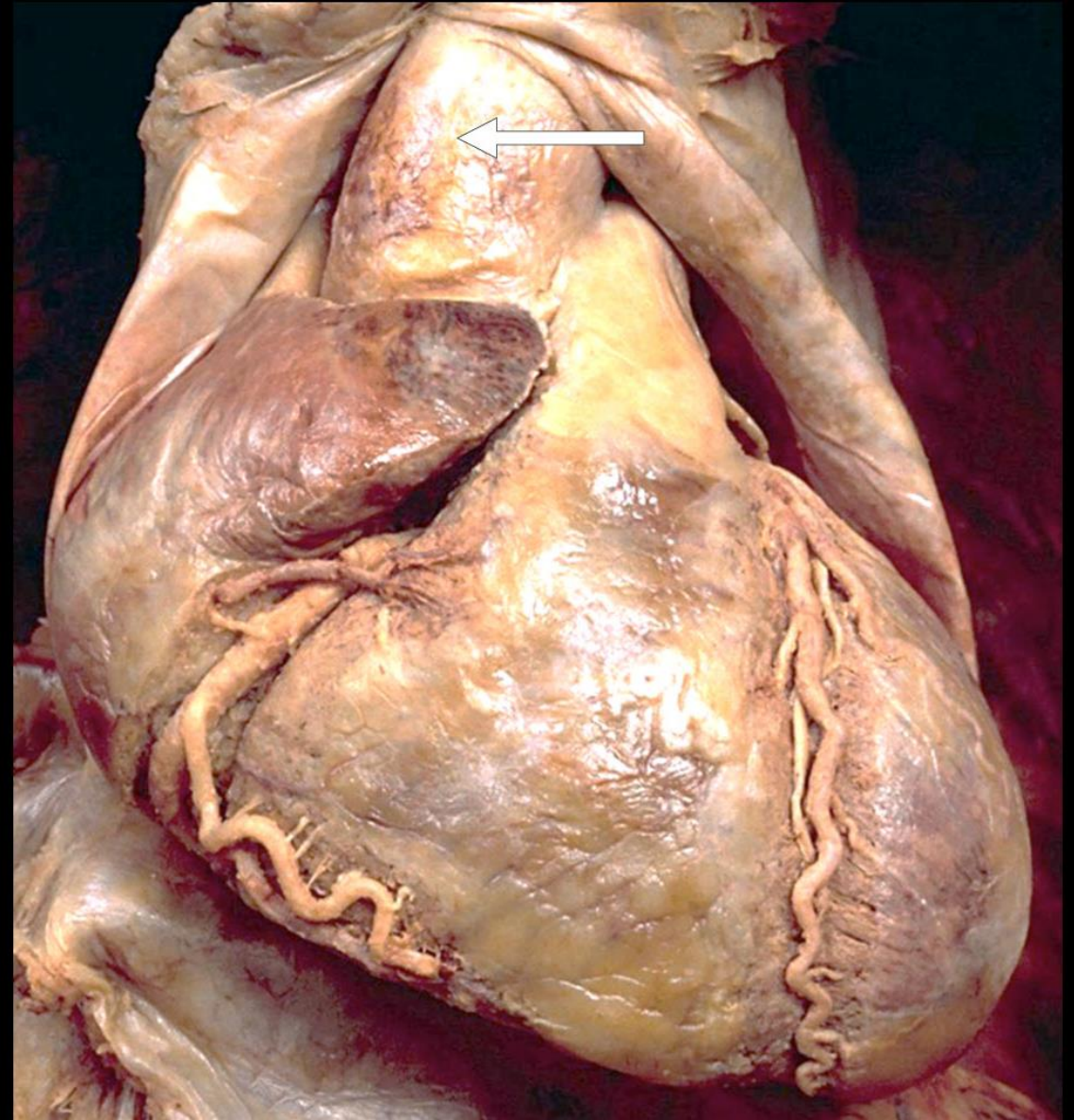
Anterior
interventricular
artery



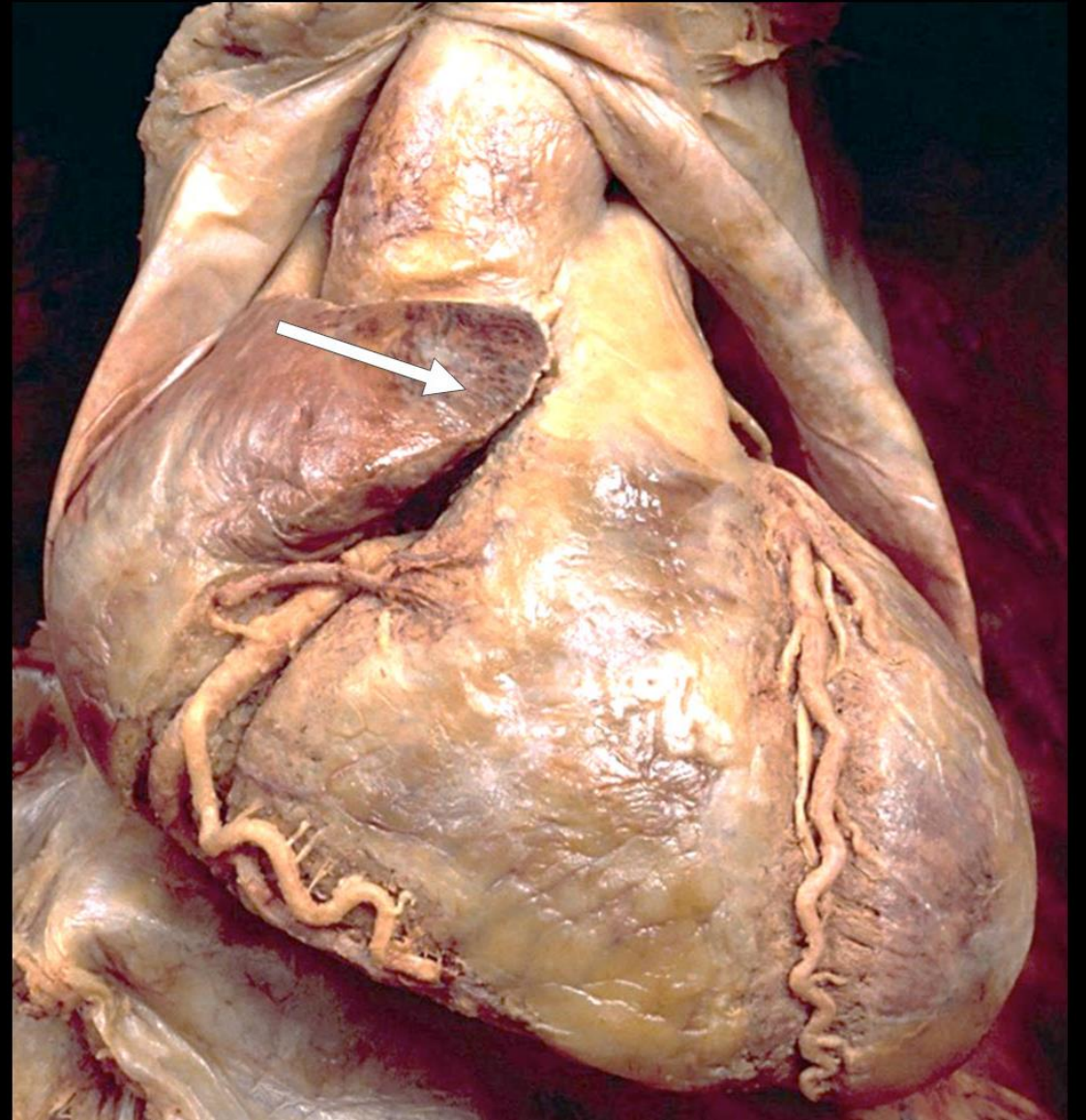
Pulmonary trunk



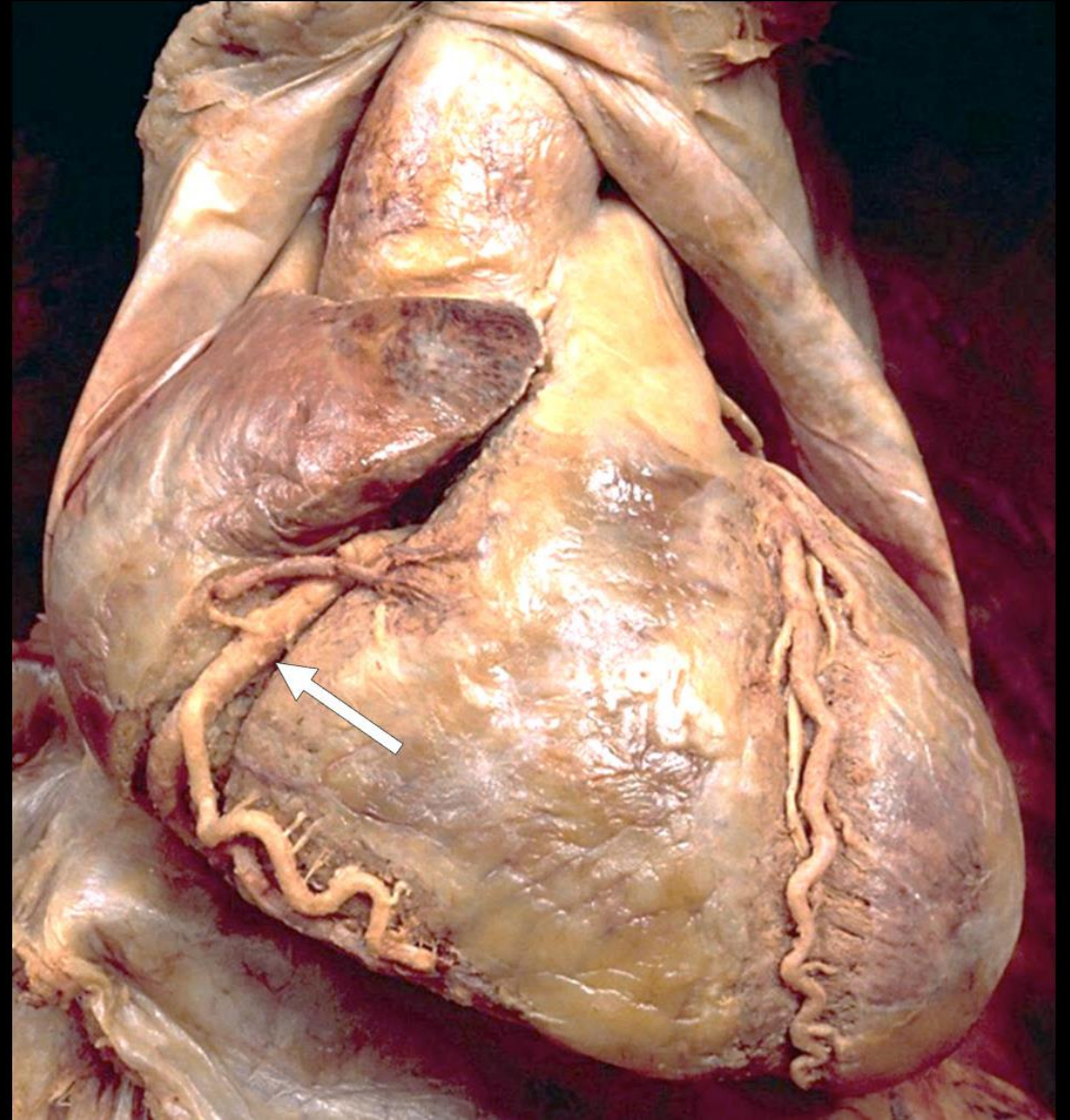
Ascending aorta



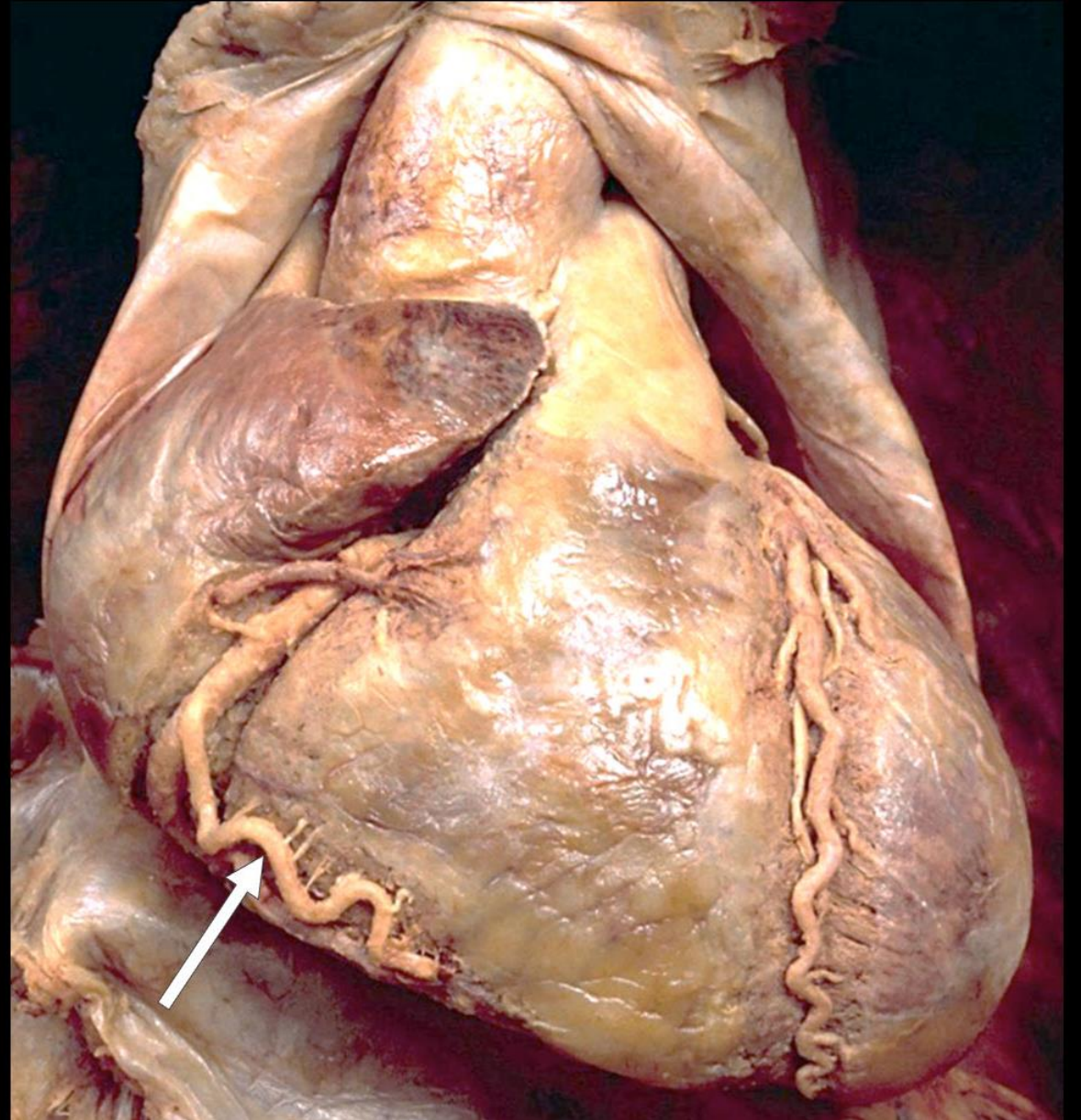
Right auricle



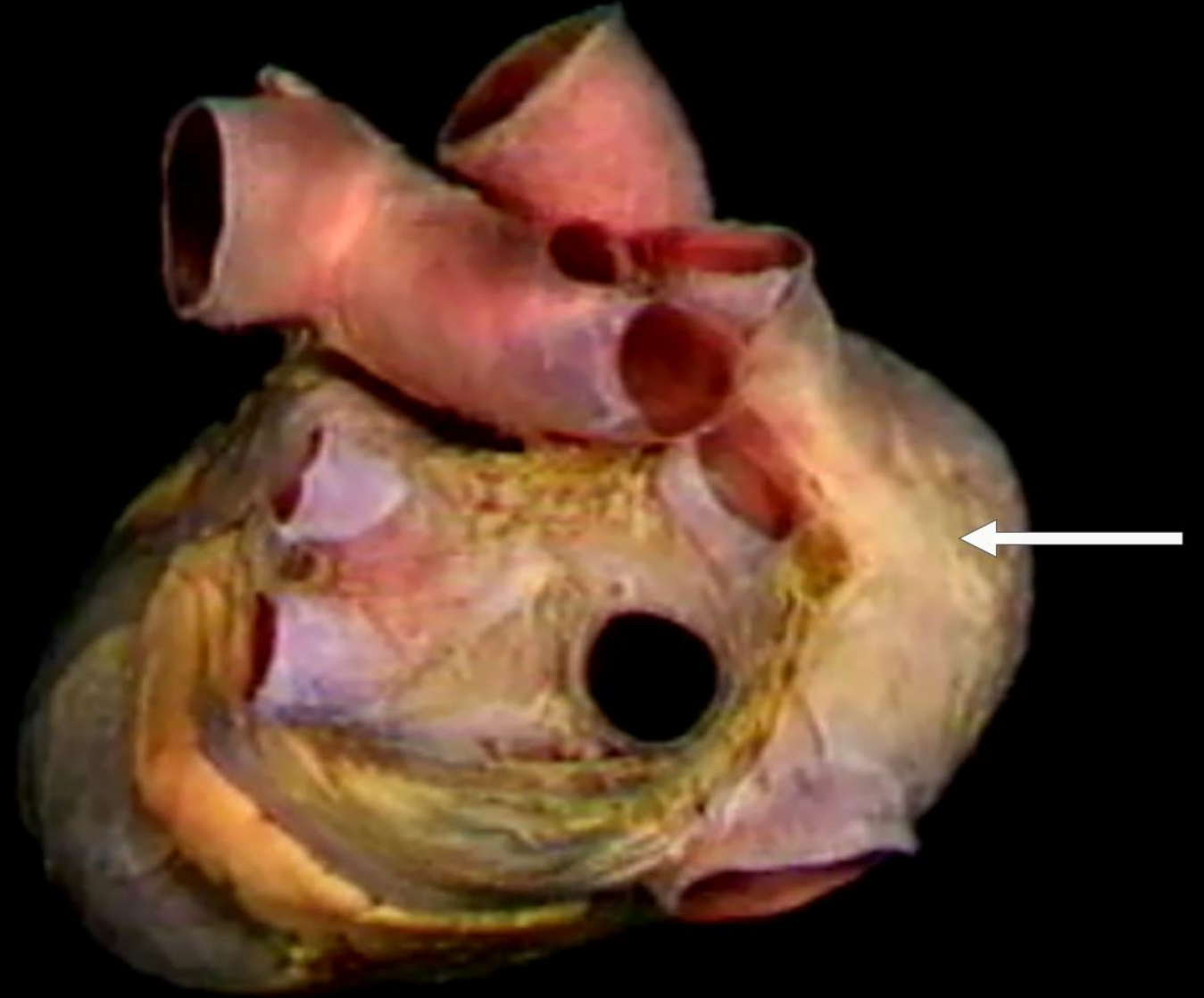
Right coronary



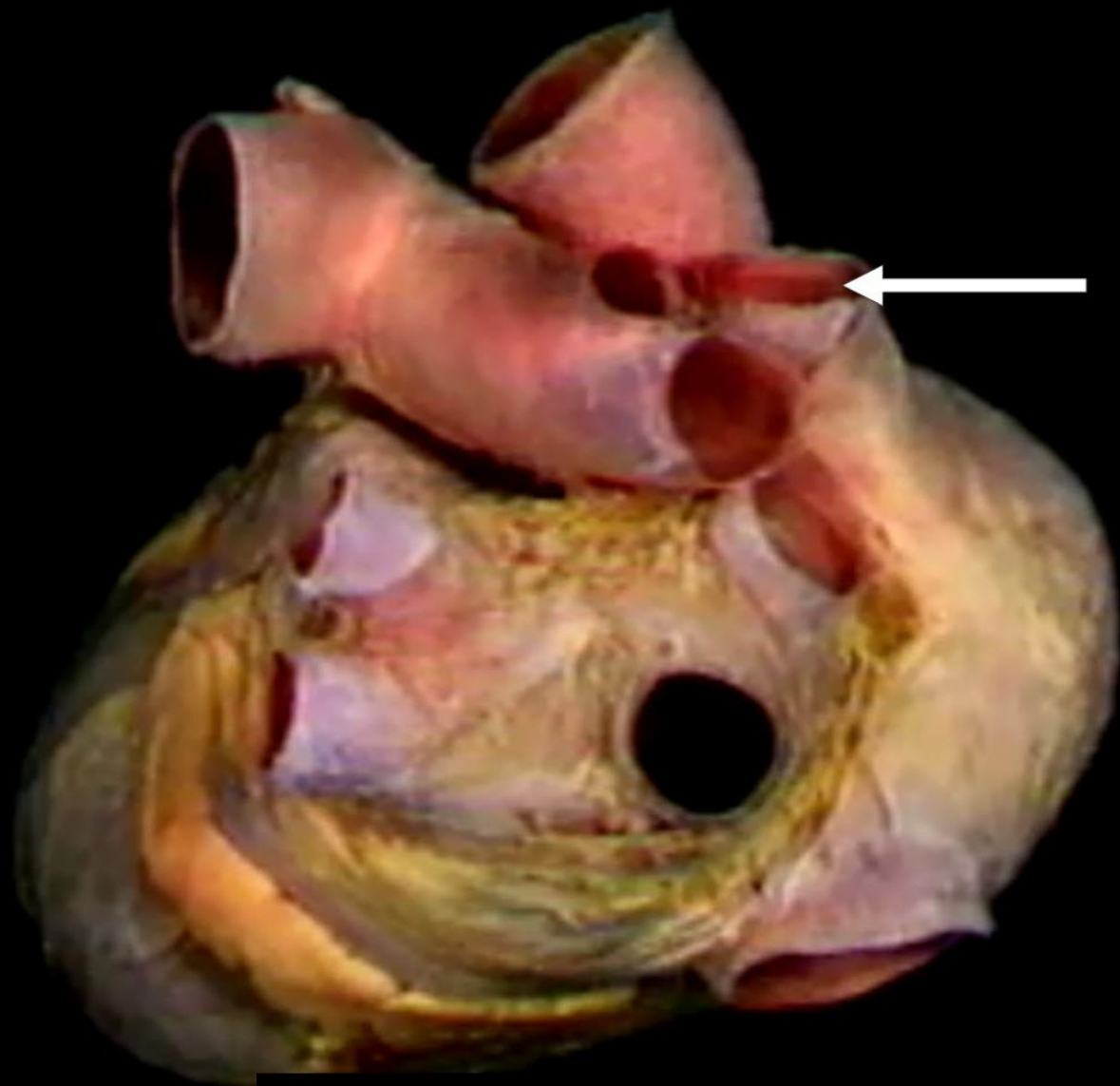
Right marginal artery



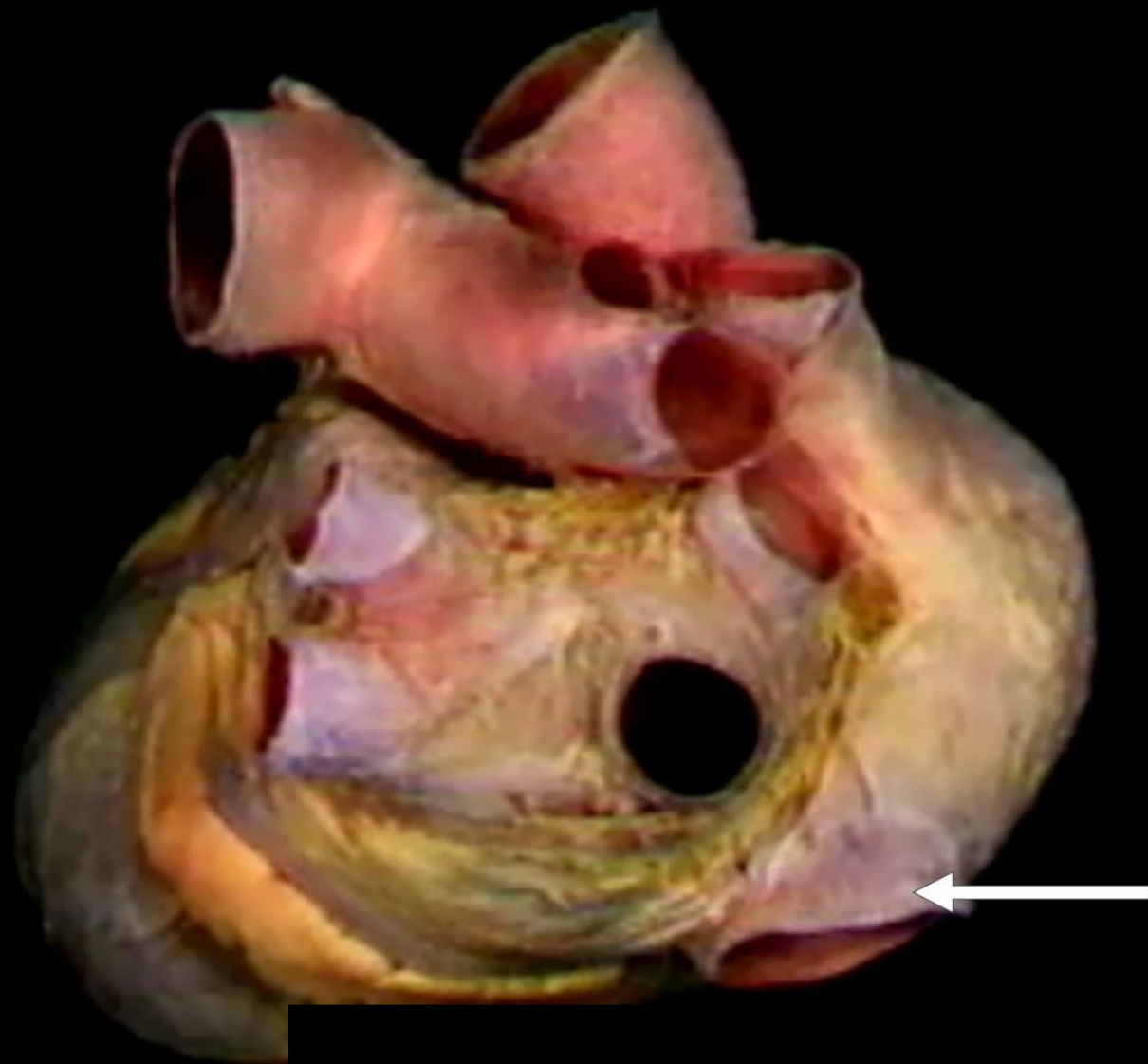
Right atrium



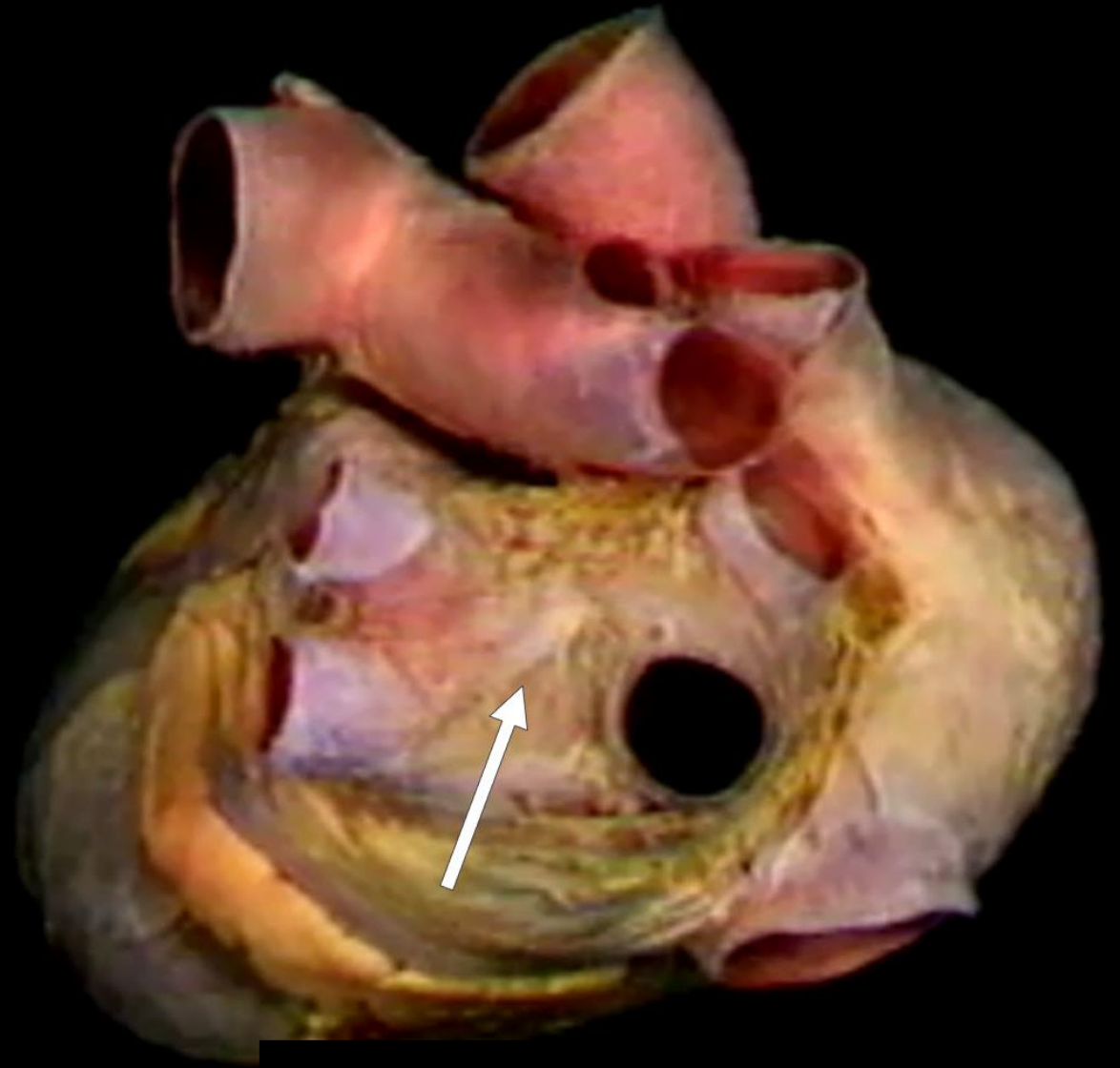
SVC



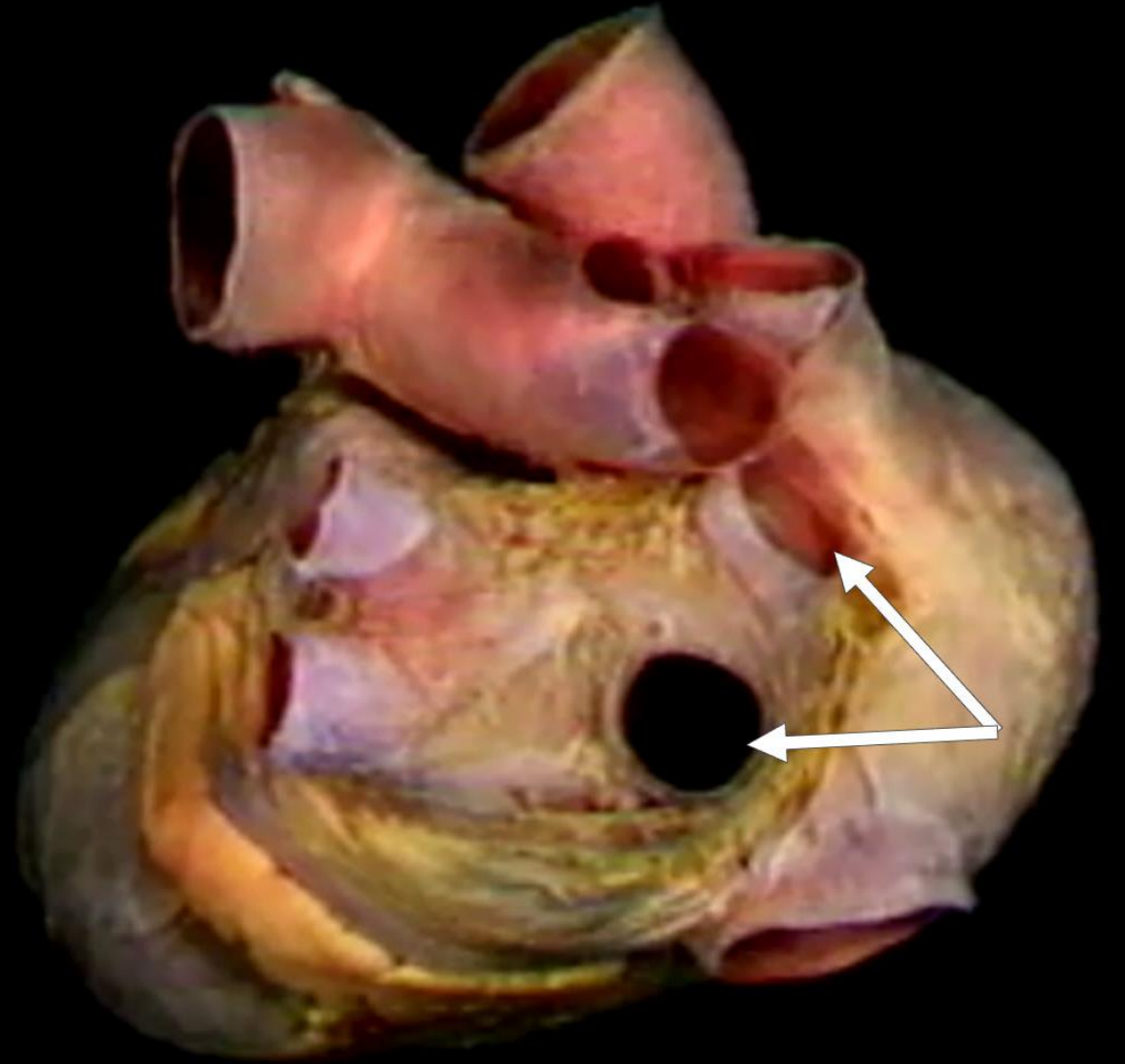
IVC



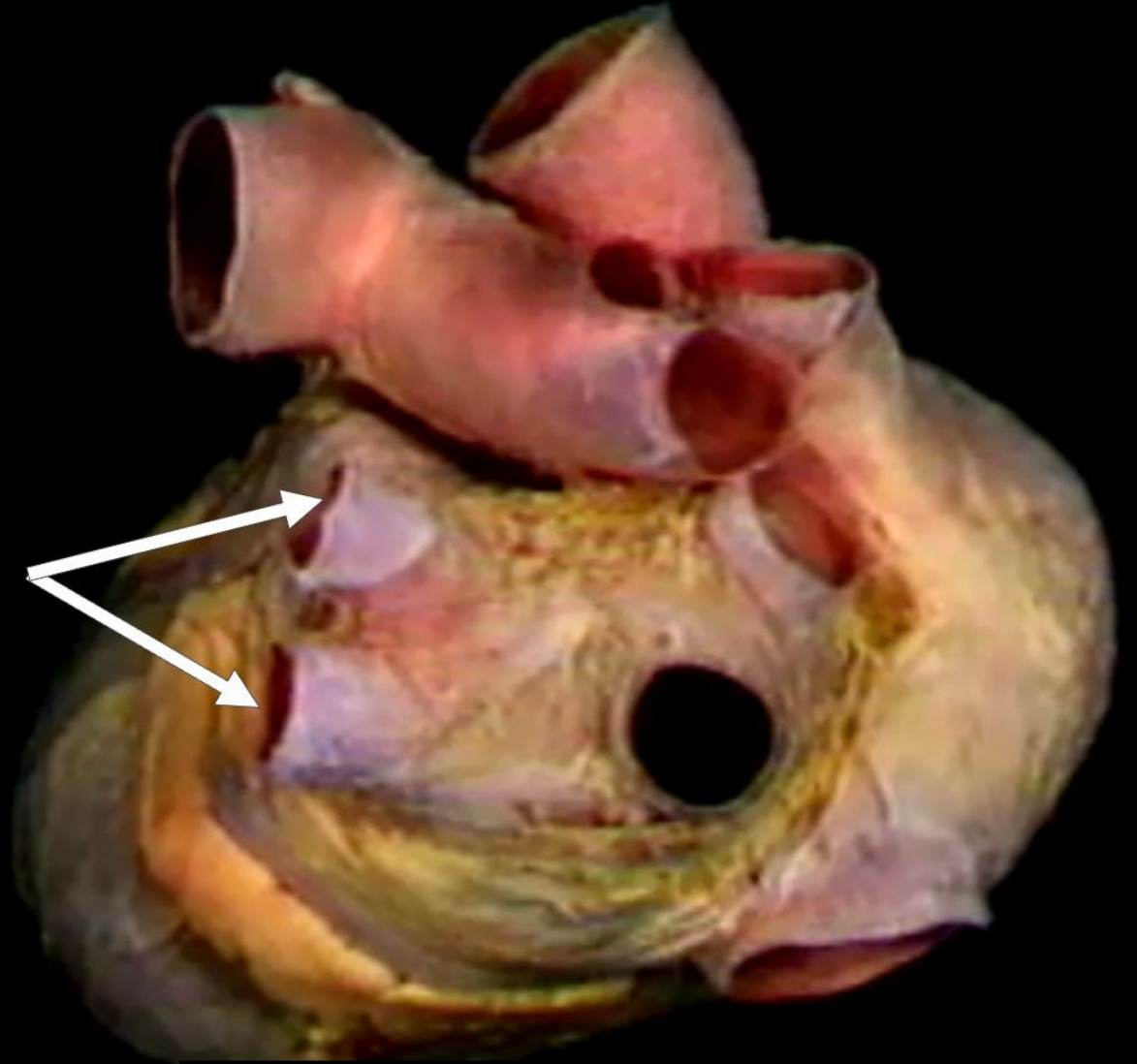
Left atrium



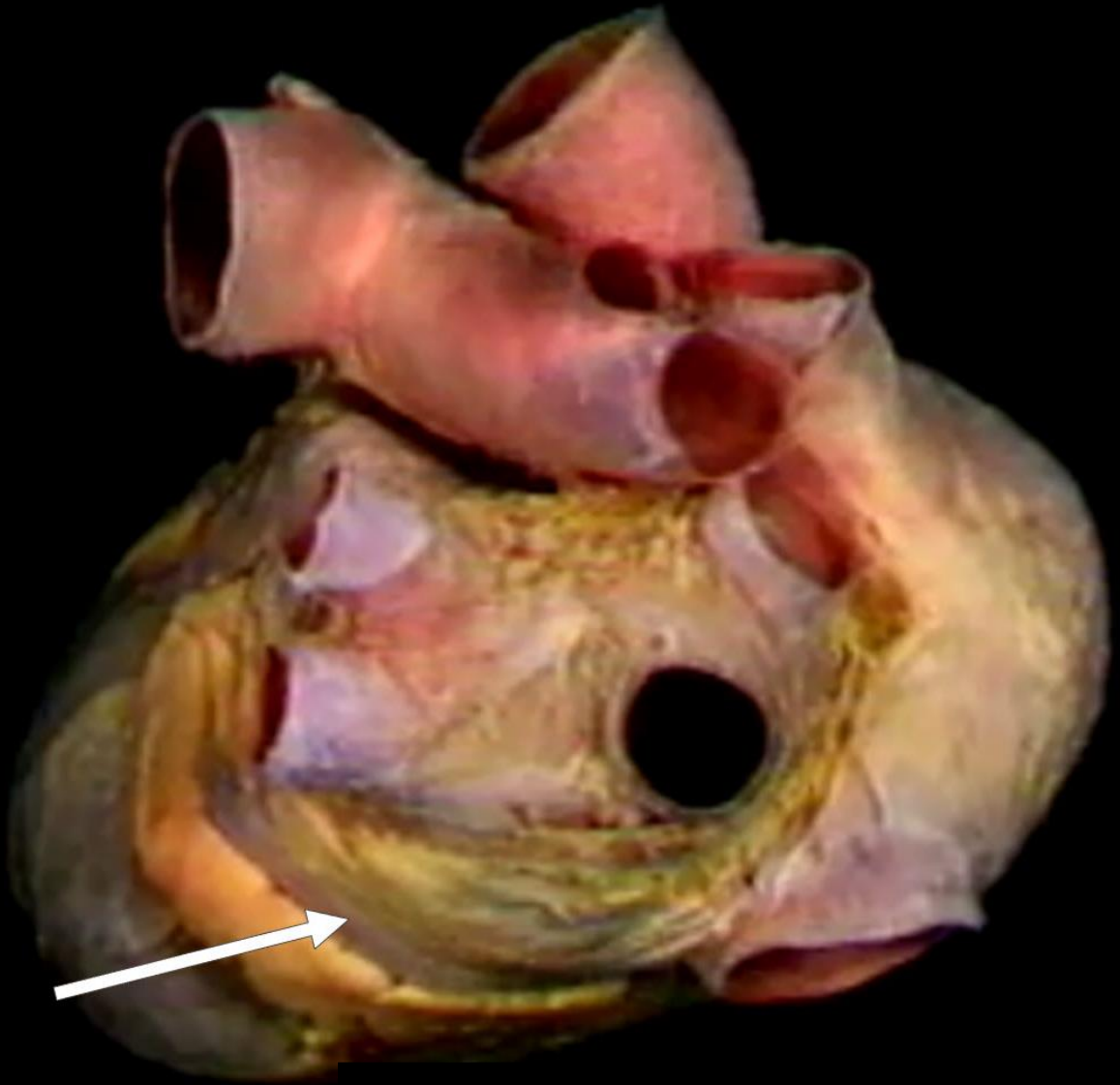
Right pulmonary veins



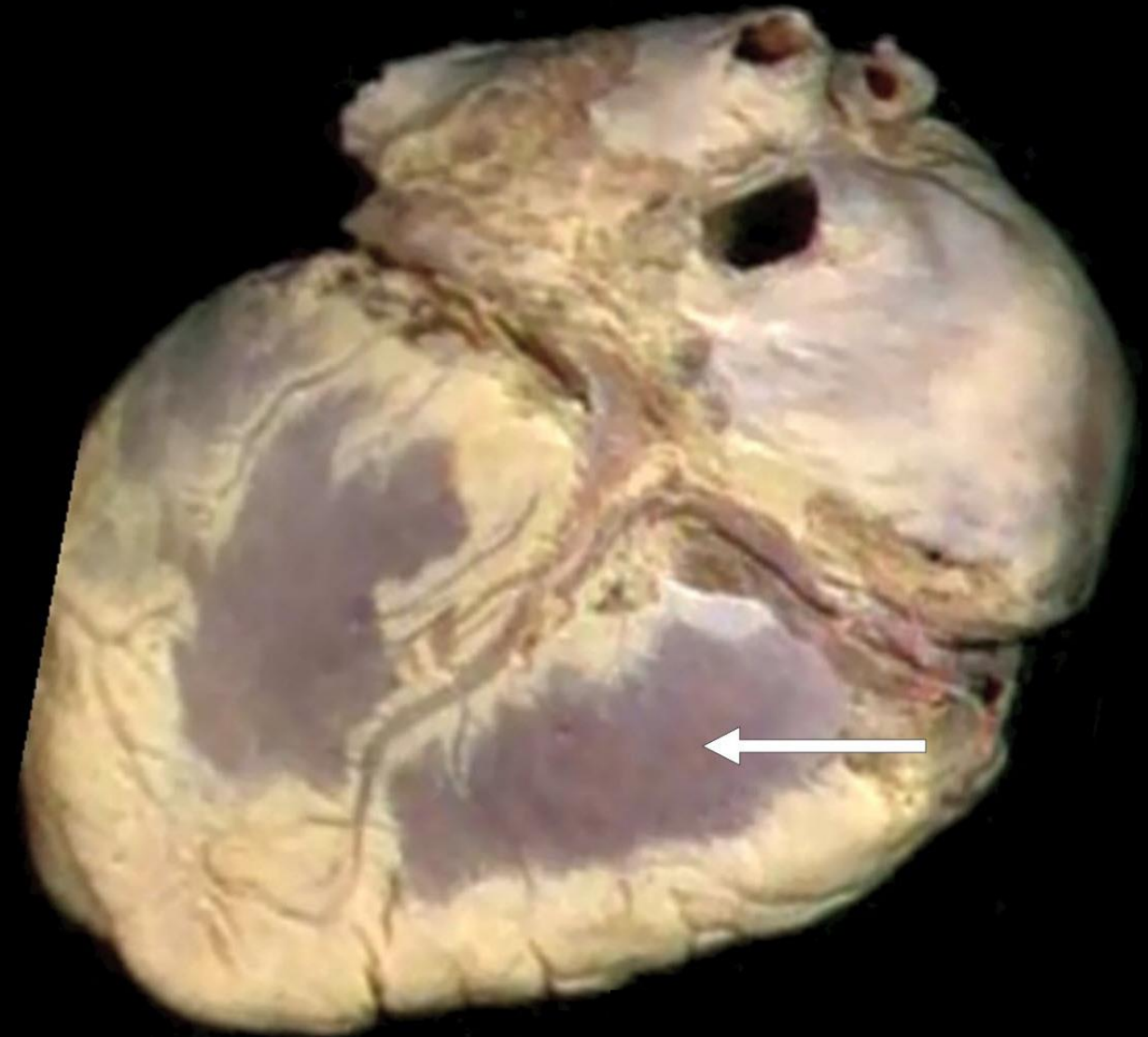
Left Pulmonary Veins



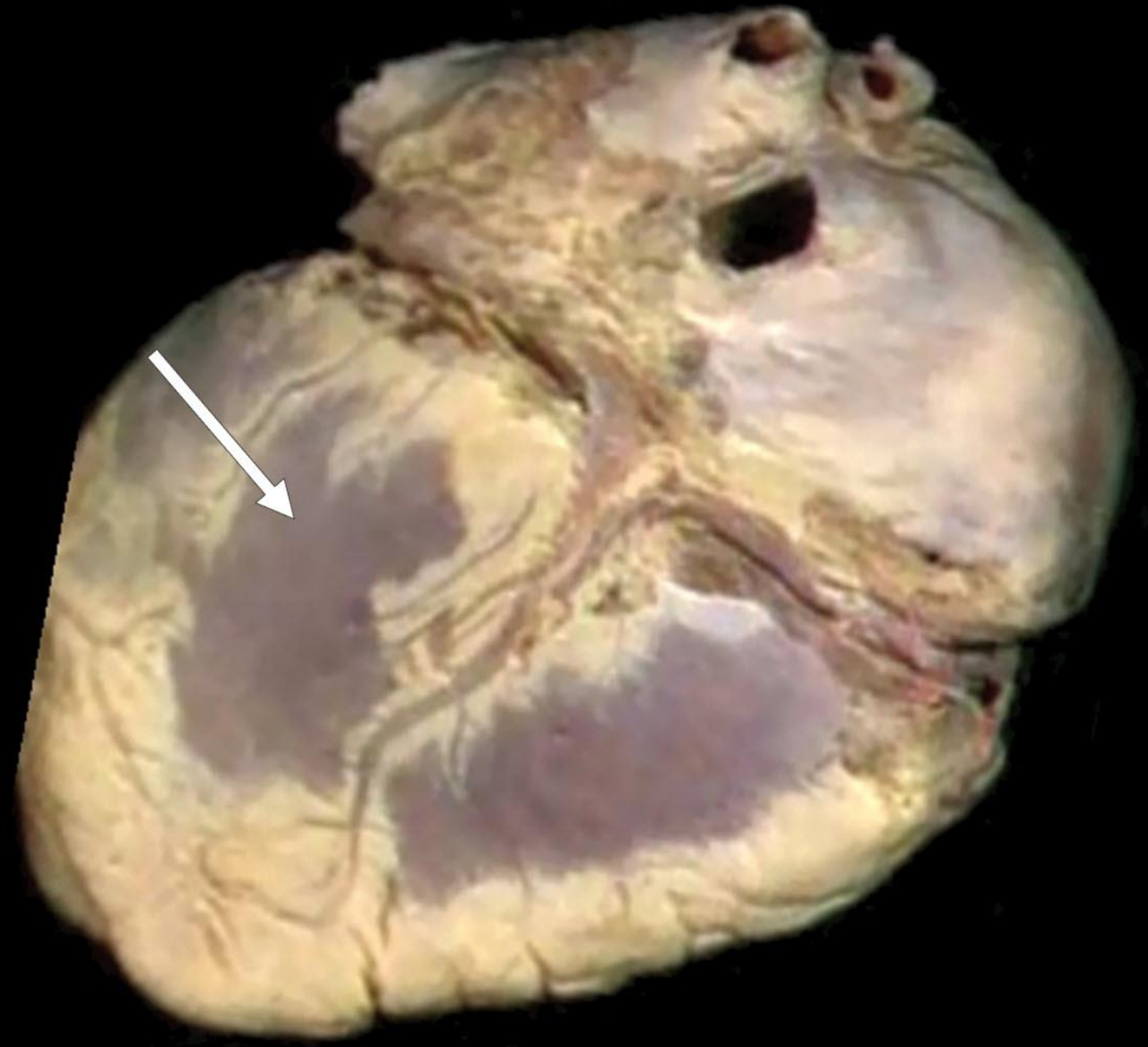
Coronary Sinus



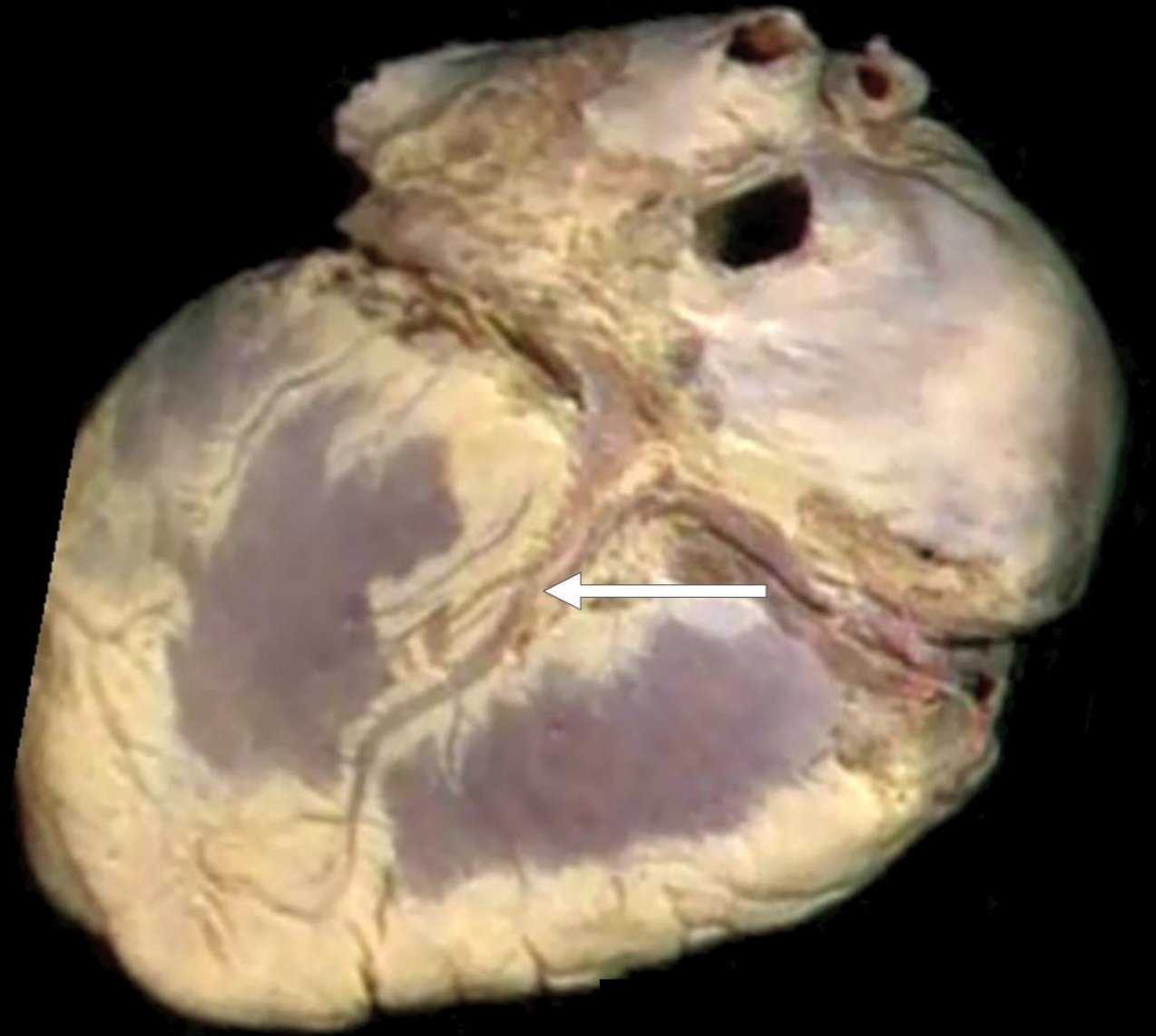
Right Ventricle
(Diaphragmatic
Surface)



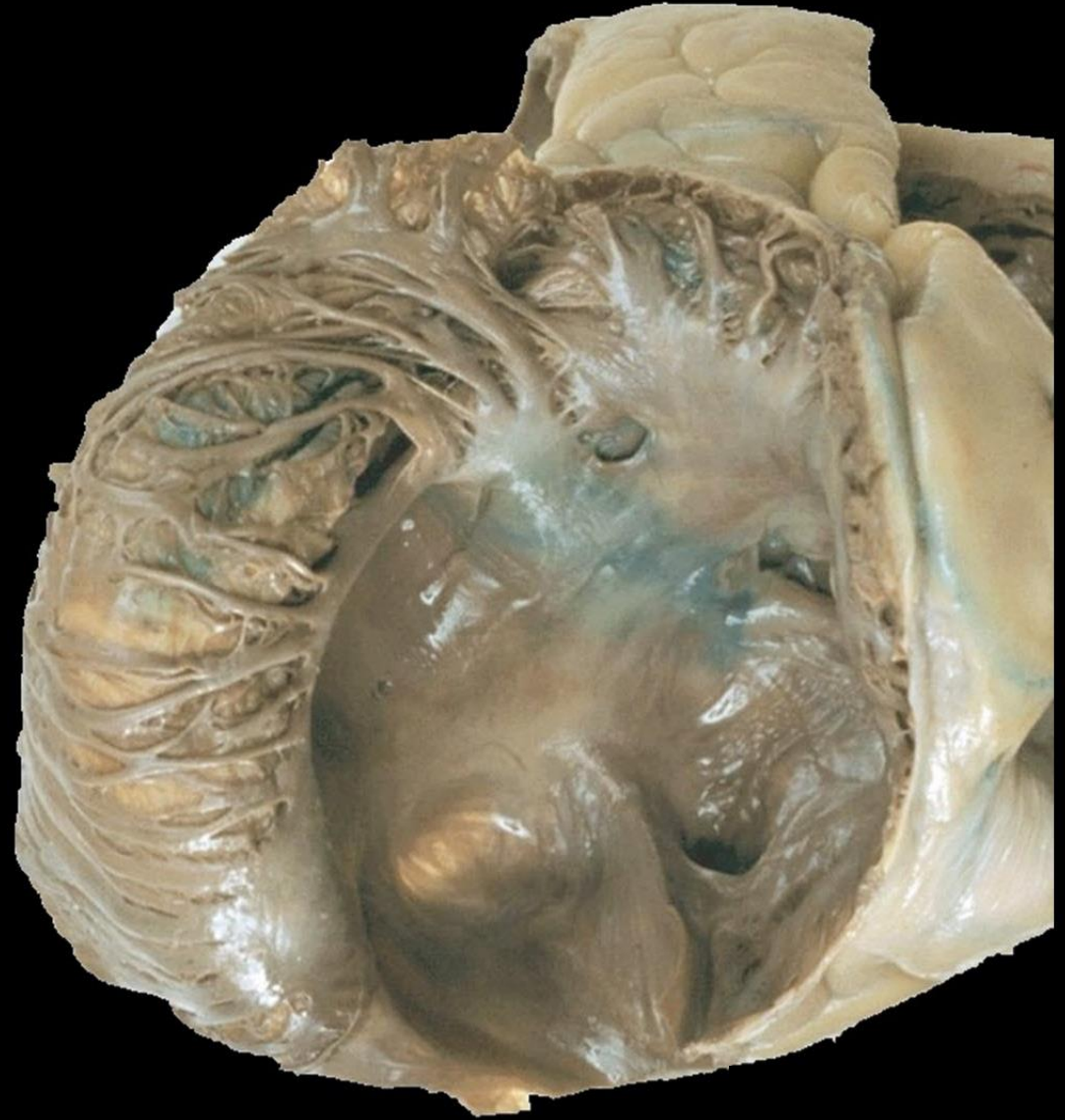Left Ventricle
(Diaphragmatic
Surface)



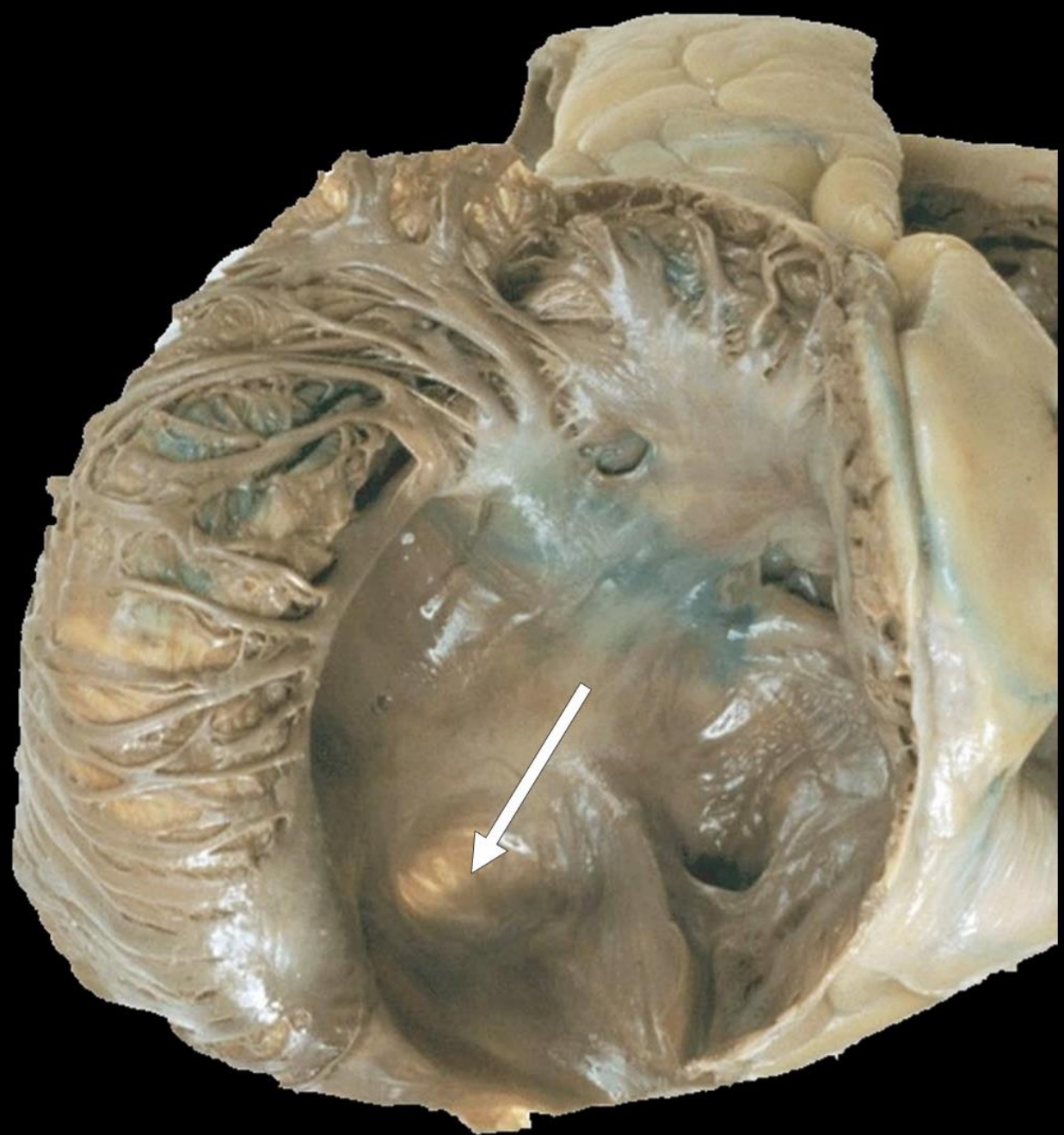Posterior
Interventricular
Groove
(containing The
Posterior
Interventricular
Artery and The
Middle Cardiac Vein)



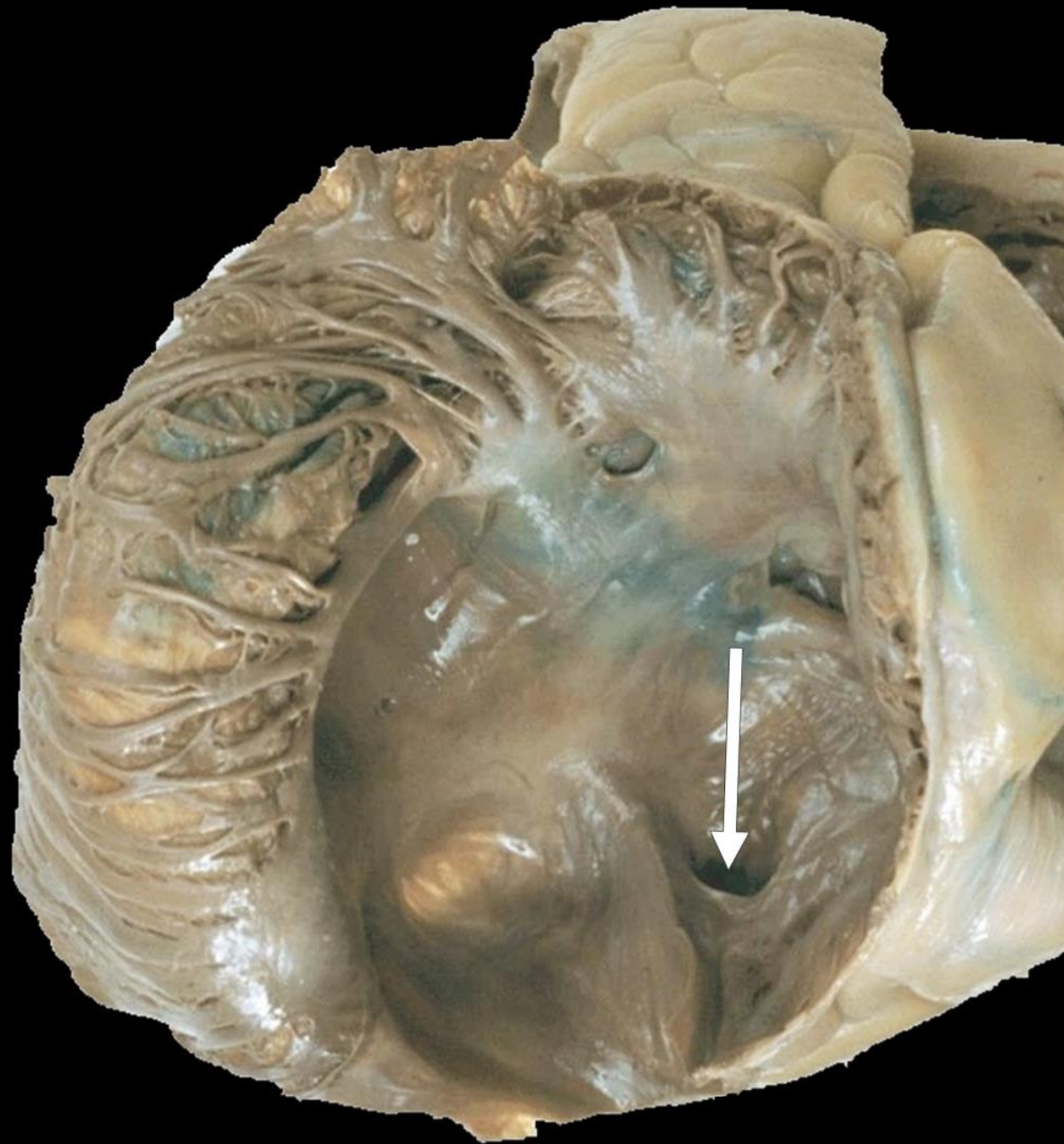
Right Atrium



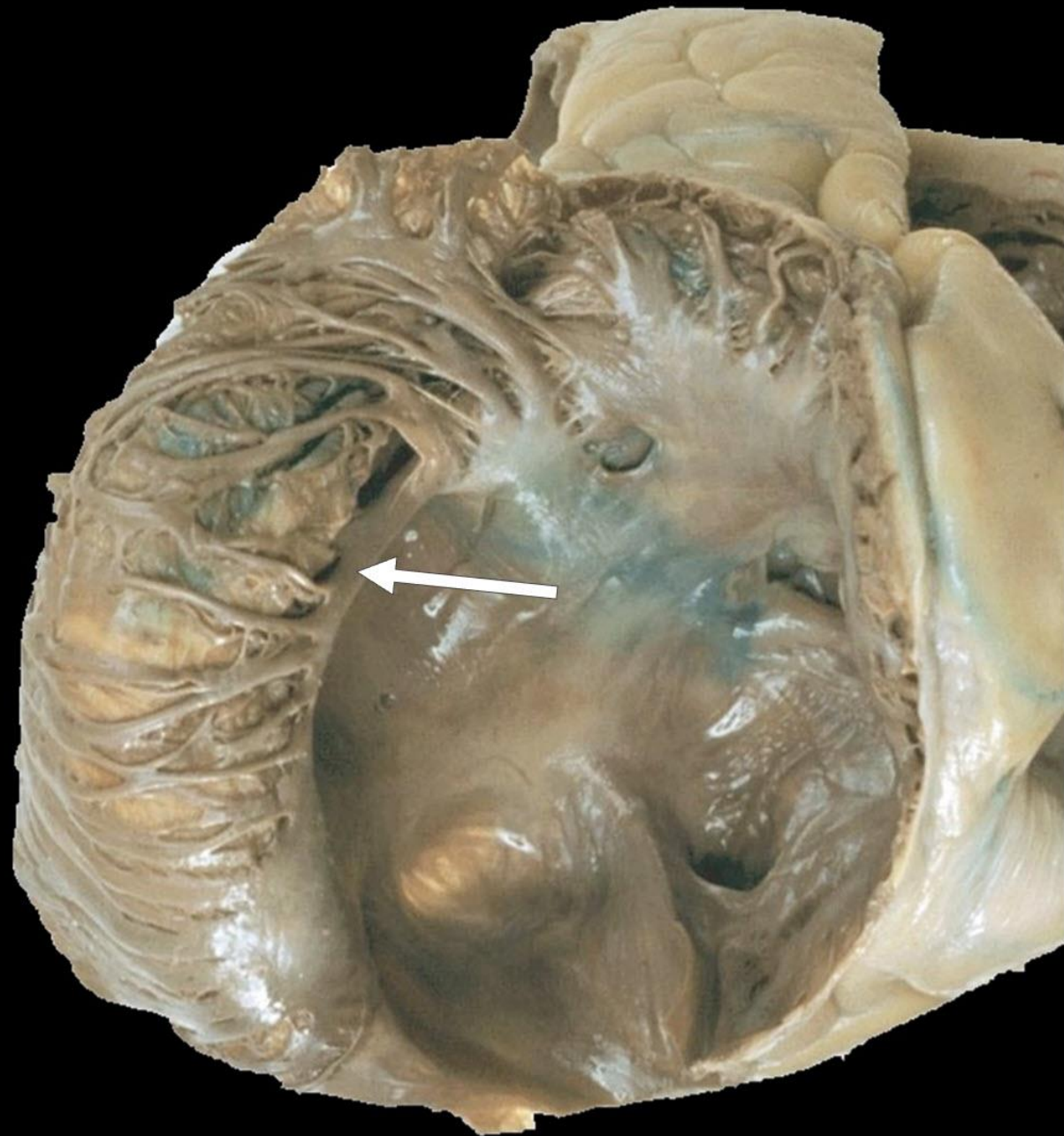
Fossa Ovalis



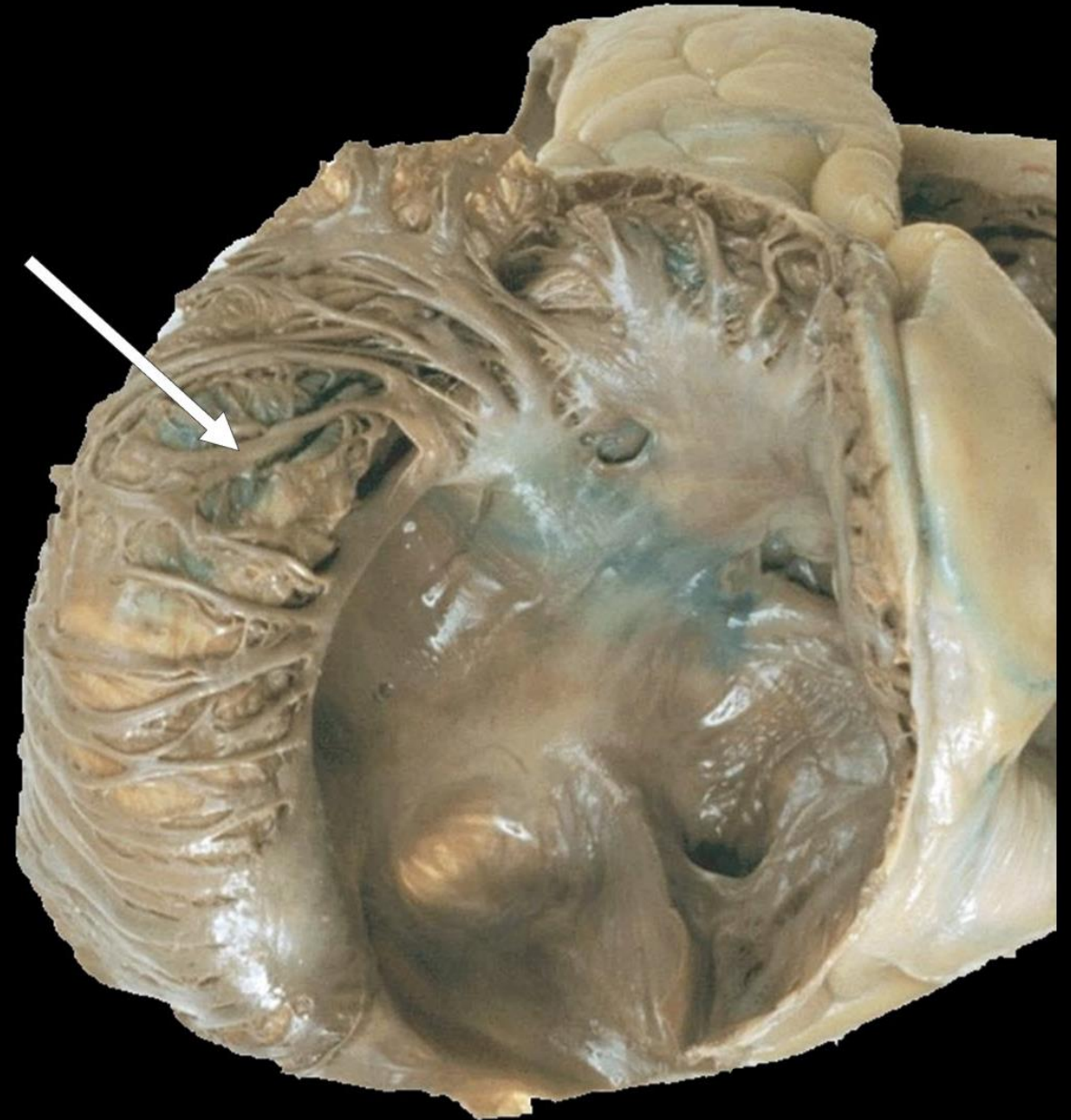Opening of The Coronary Sinus



Crista Terminalis

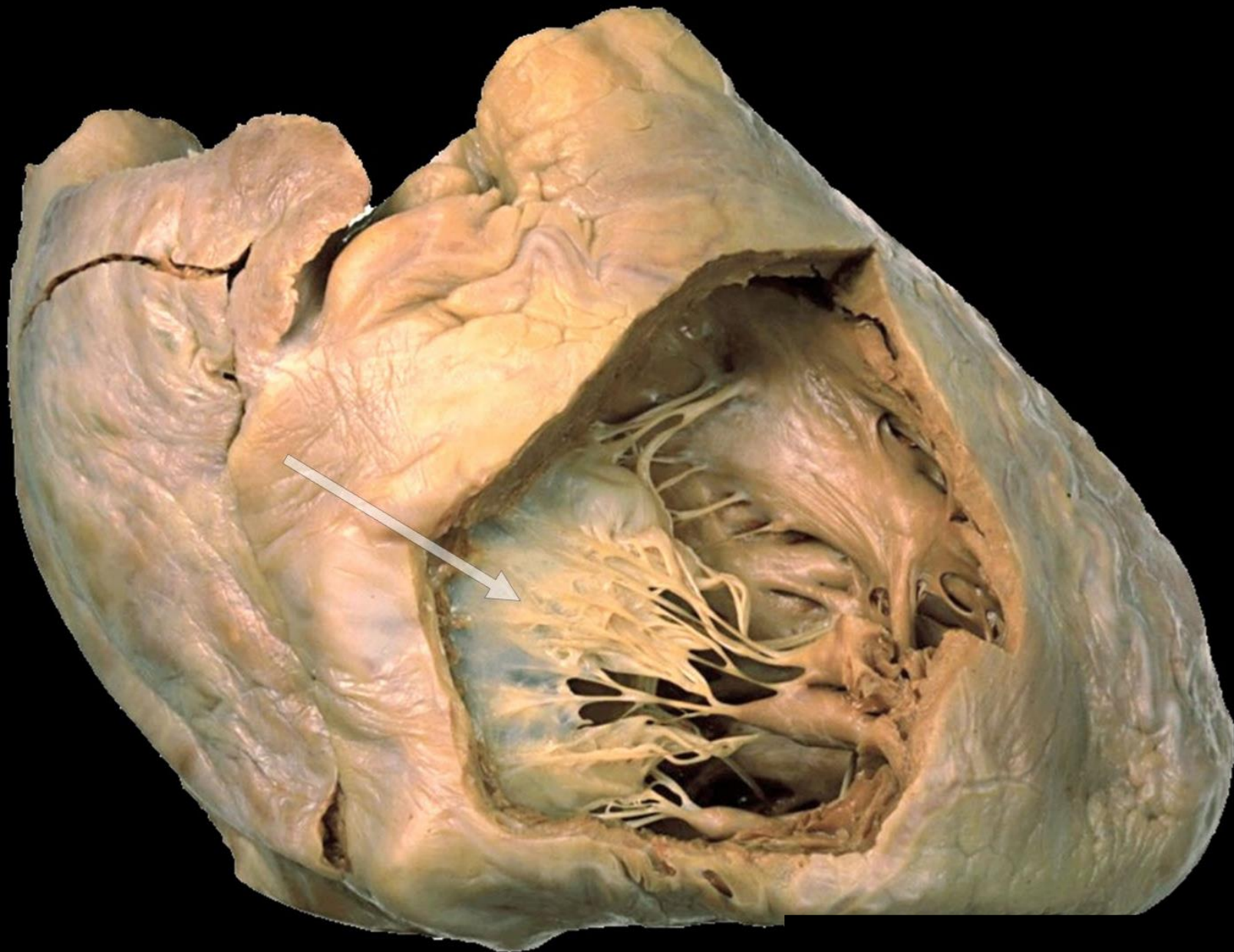


Musculi Pectinati

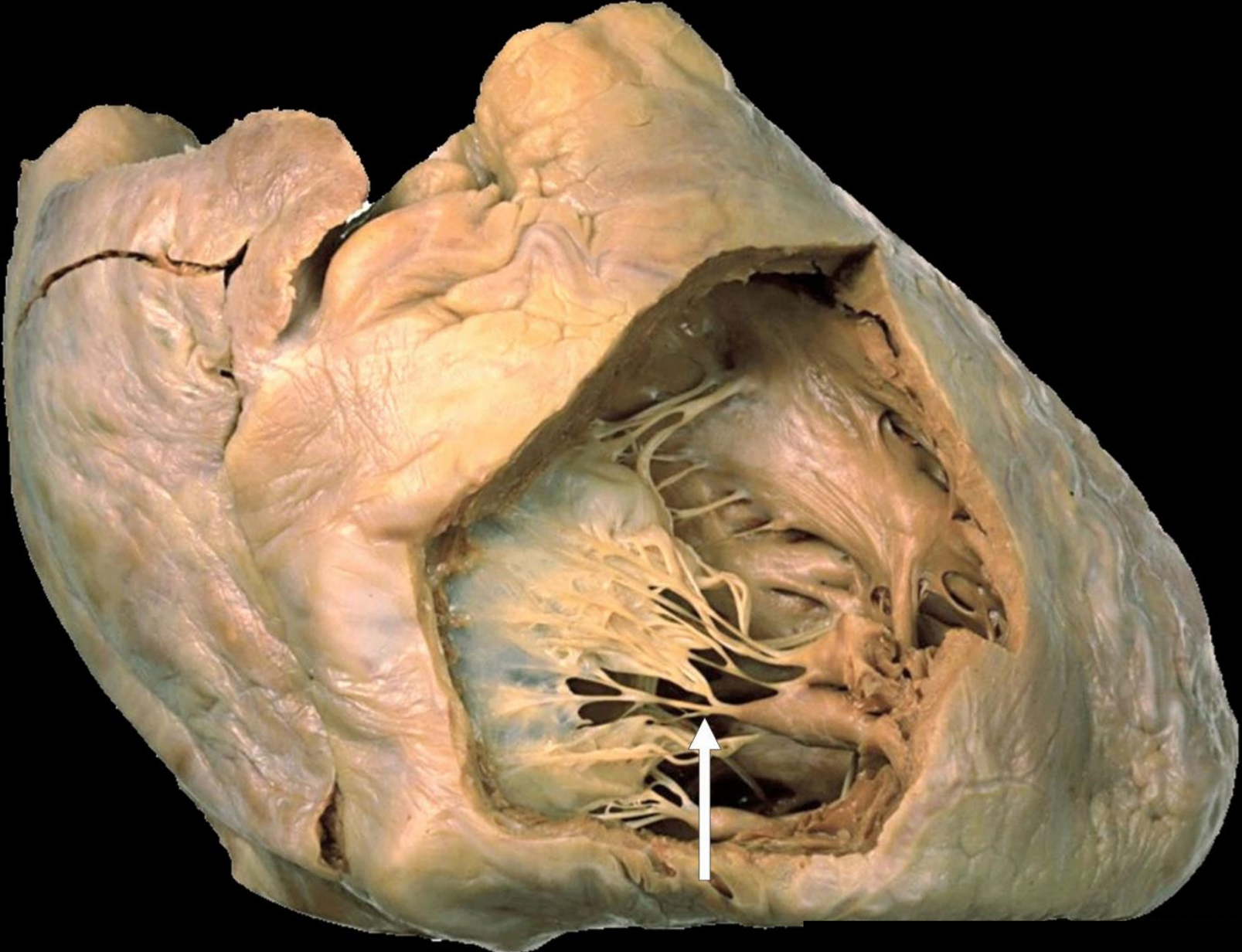


**This is The Cavity of The
Right Ventricle**

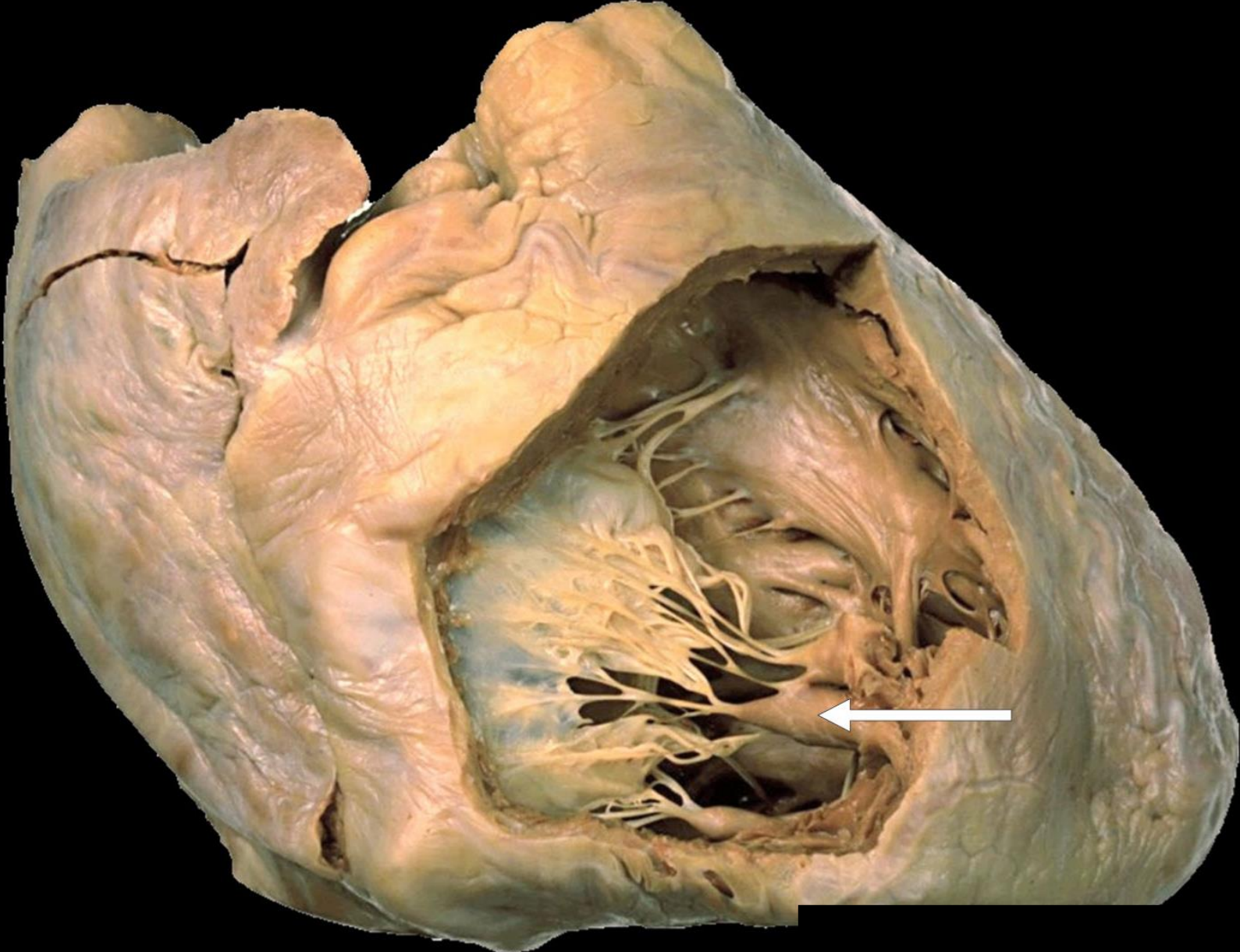
Anterior Cusp
of The
Tricuspid Valve



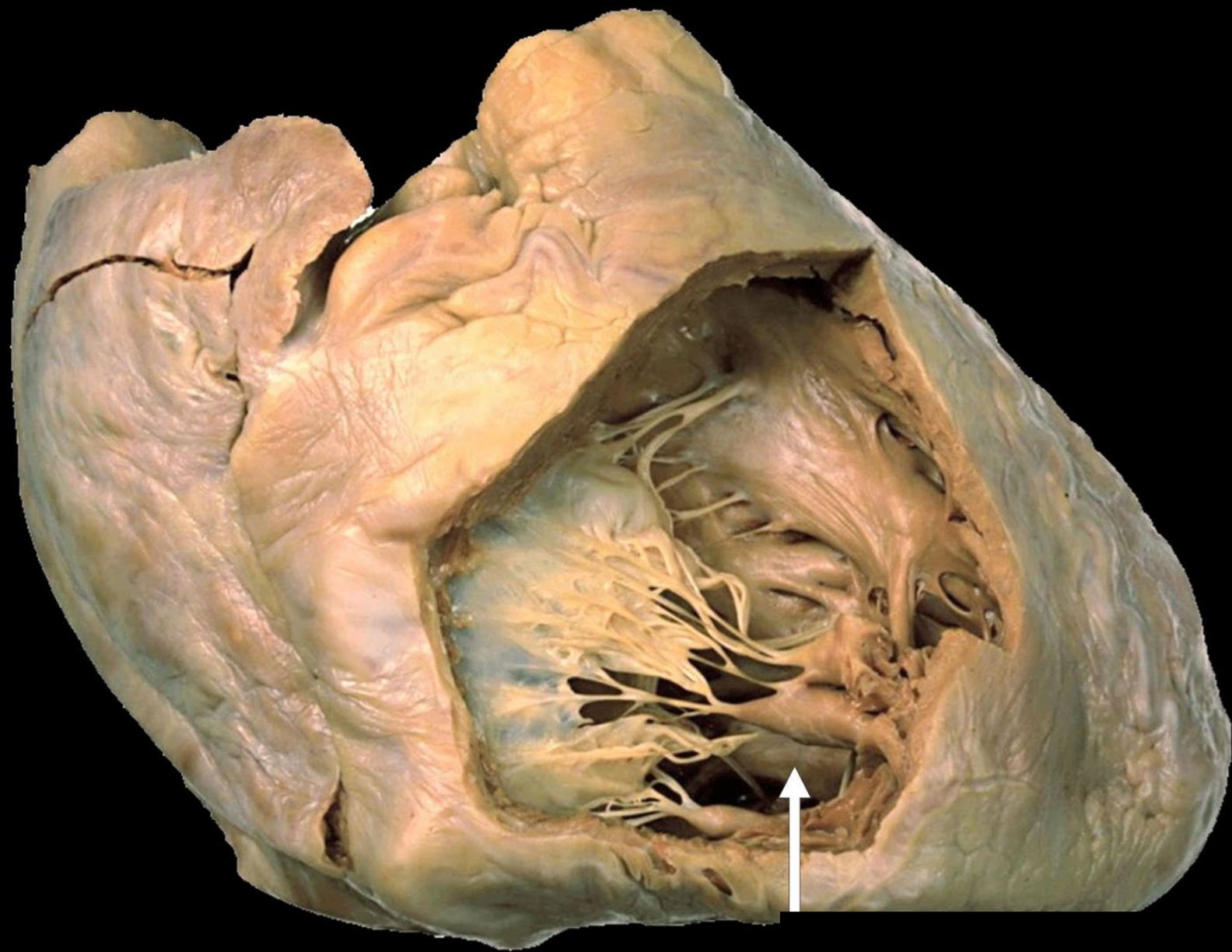
Chordae
Tendineae



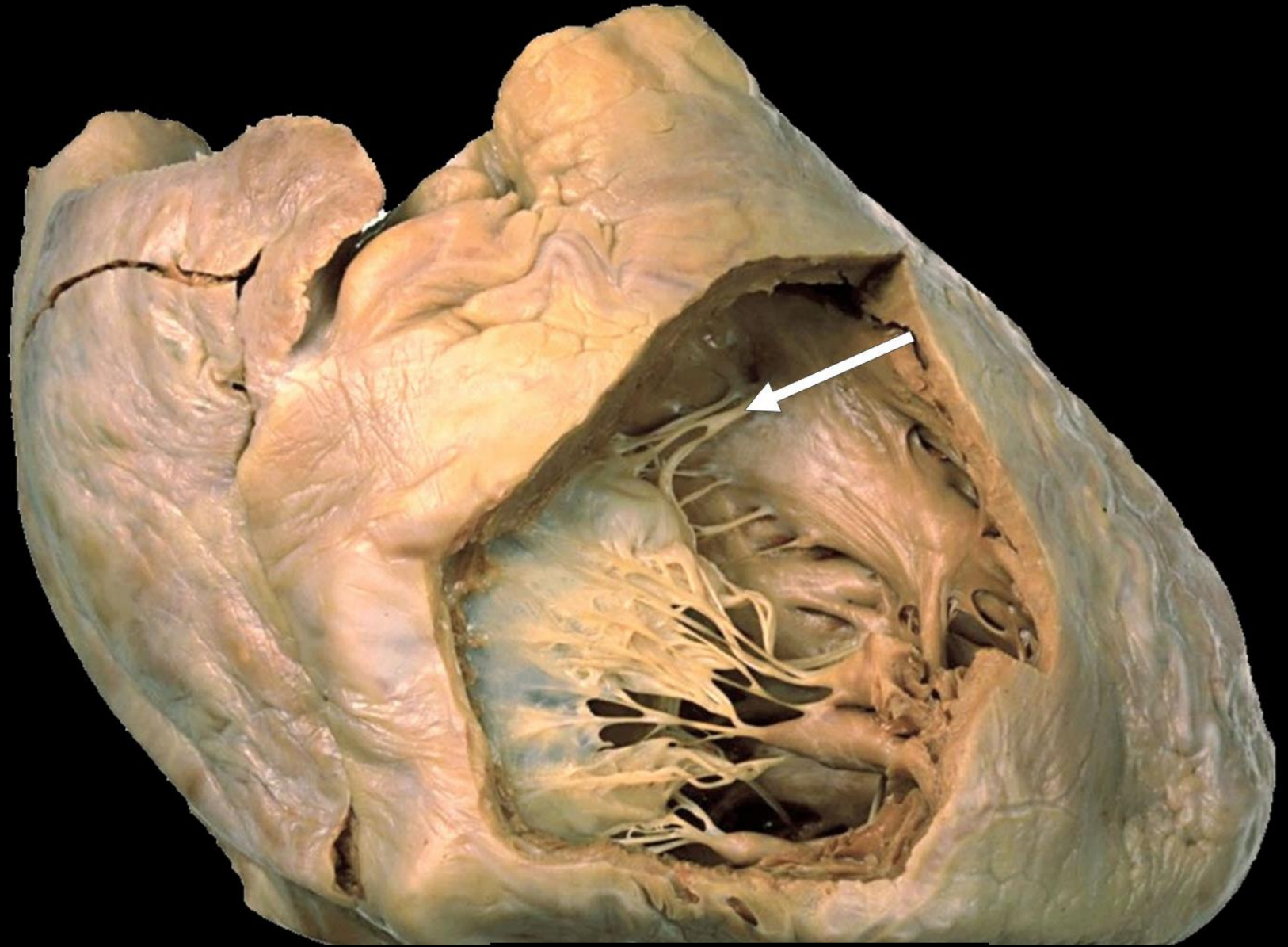
Anterior
Papillary
Muscle



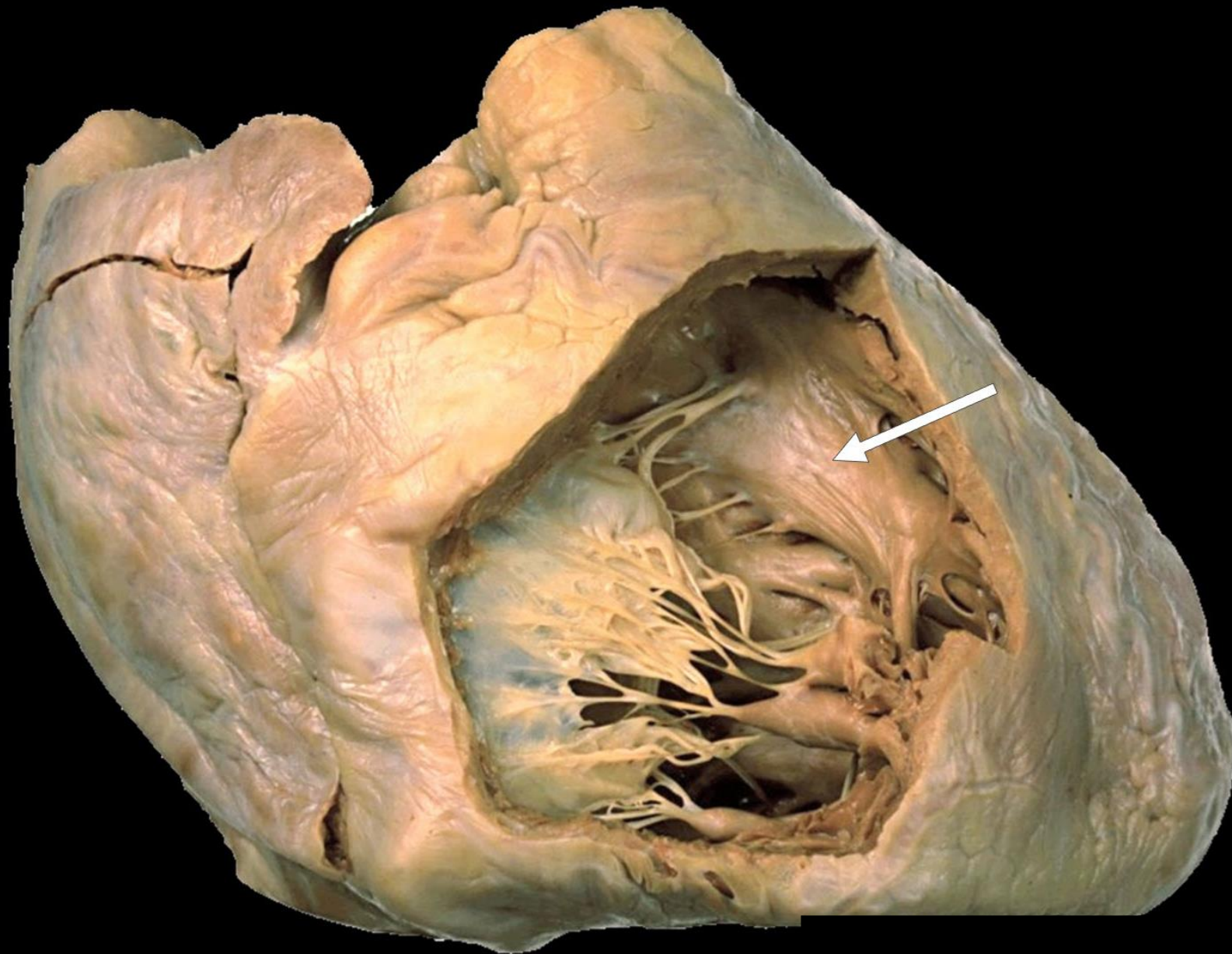
Posterior
Papillary
Muscle



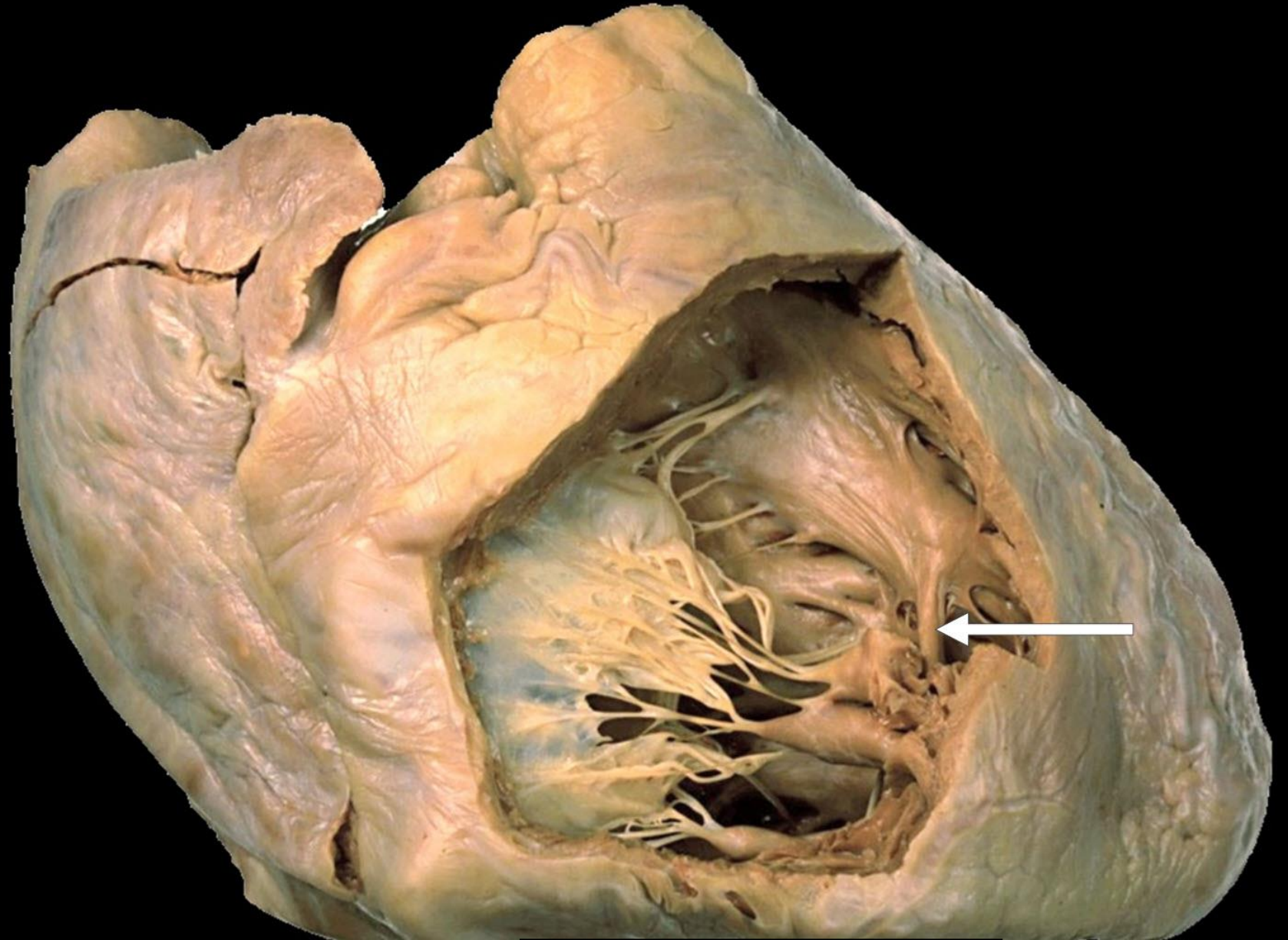
Septal
Papillary
Muscle



Interventricular
Septum

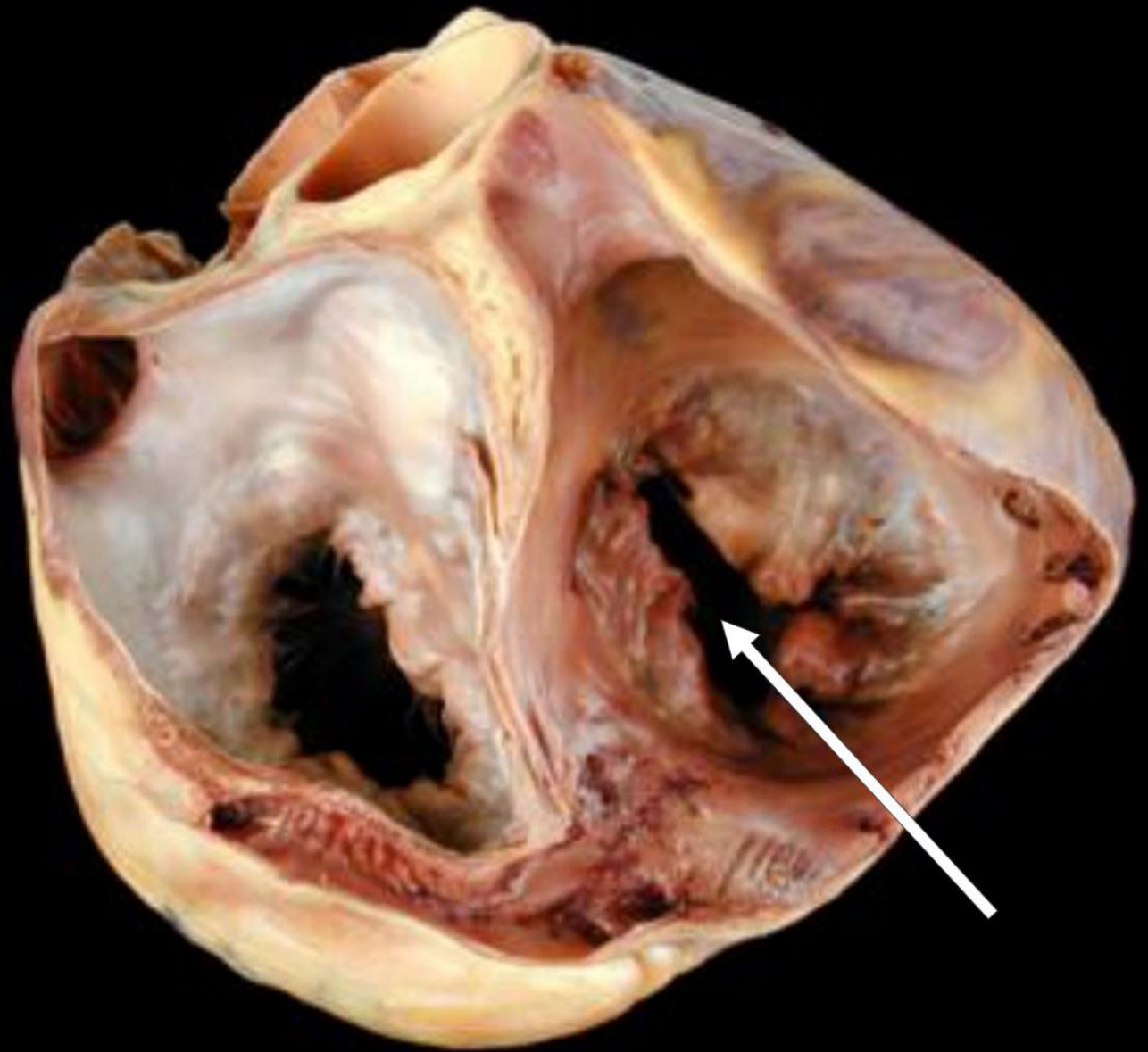


Moderator Band

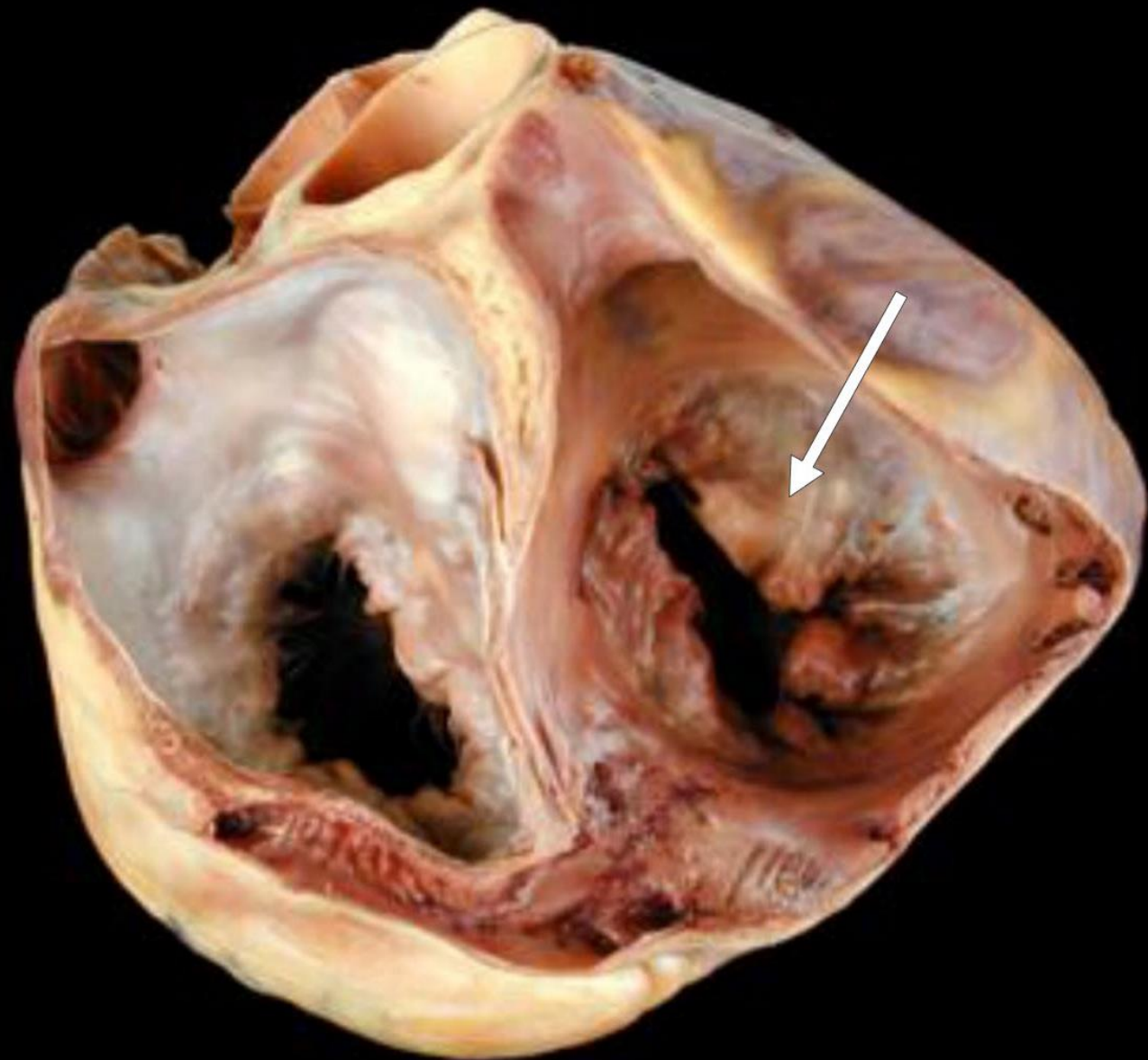


a top view of the two atria

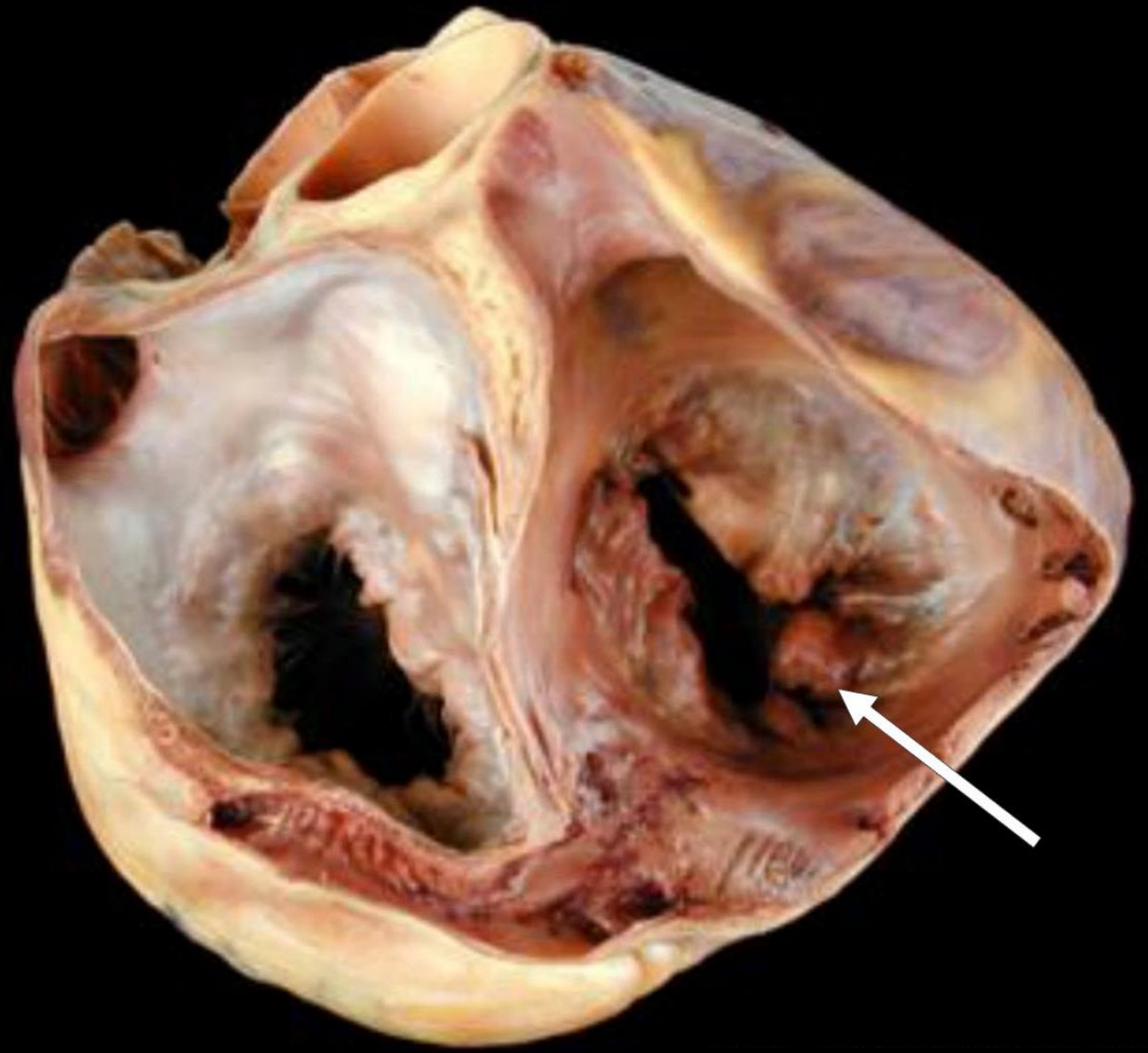
Tricuspid Orifice



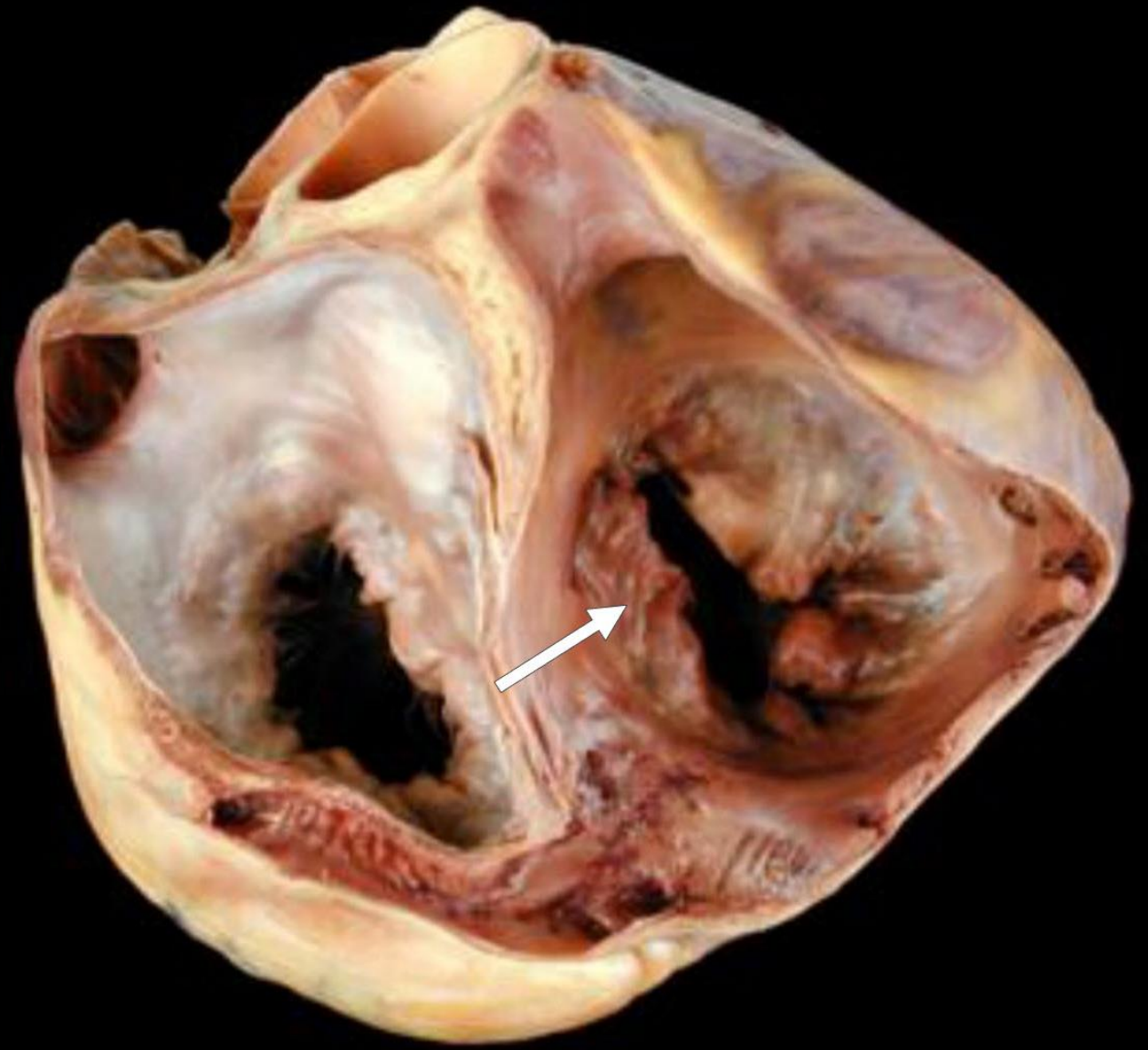
Anterior Cusp of The Tricuspid Valve



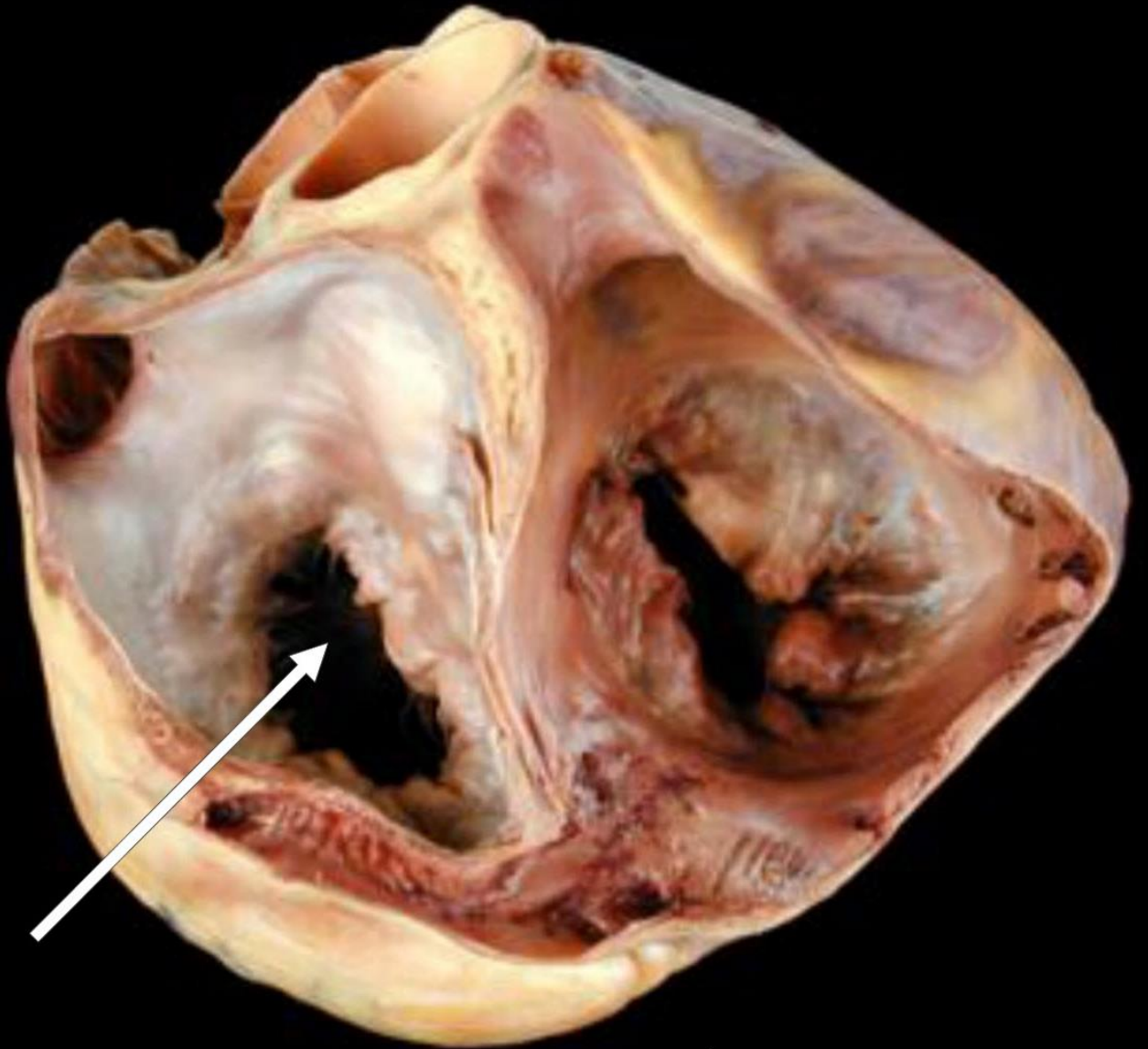
Posterior Cusp of The Tricuspid Valve



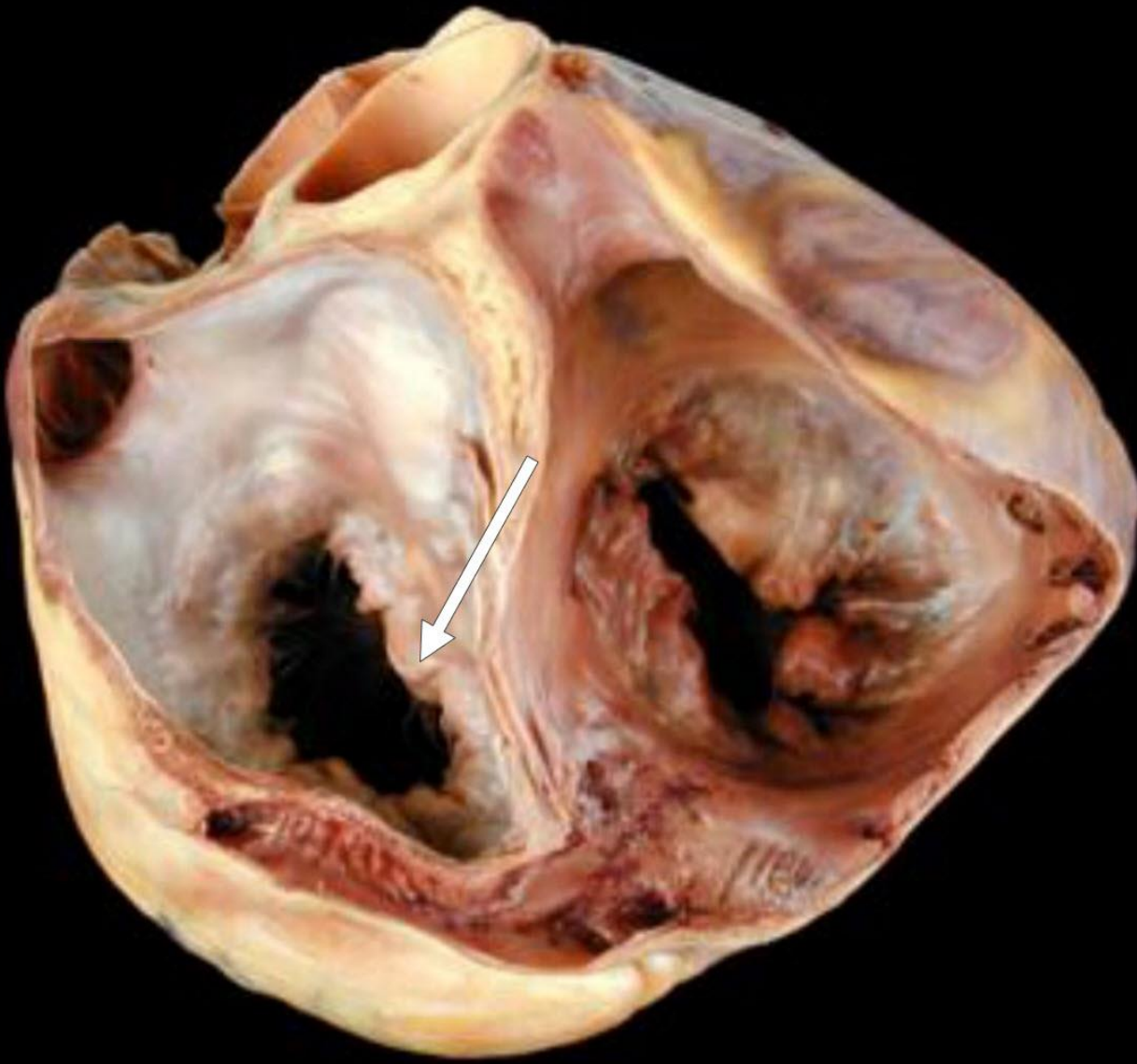
Septal Cusp of The Tricuspid Valve



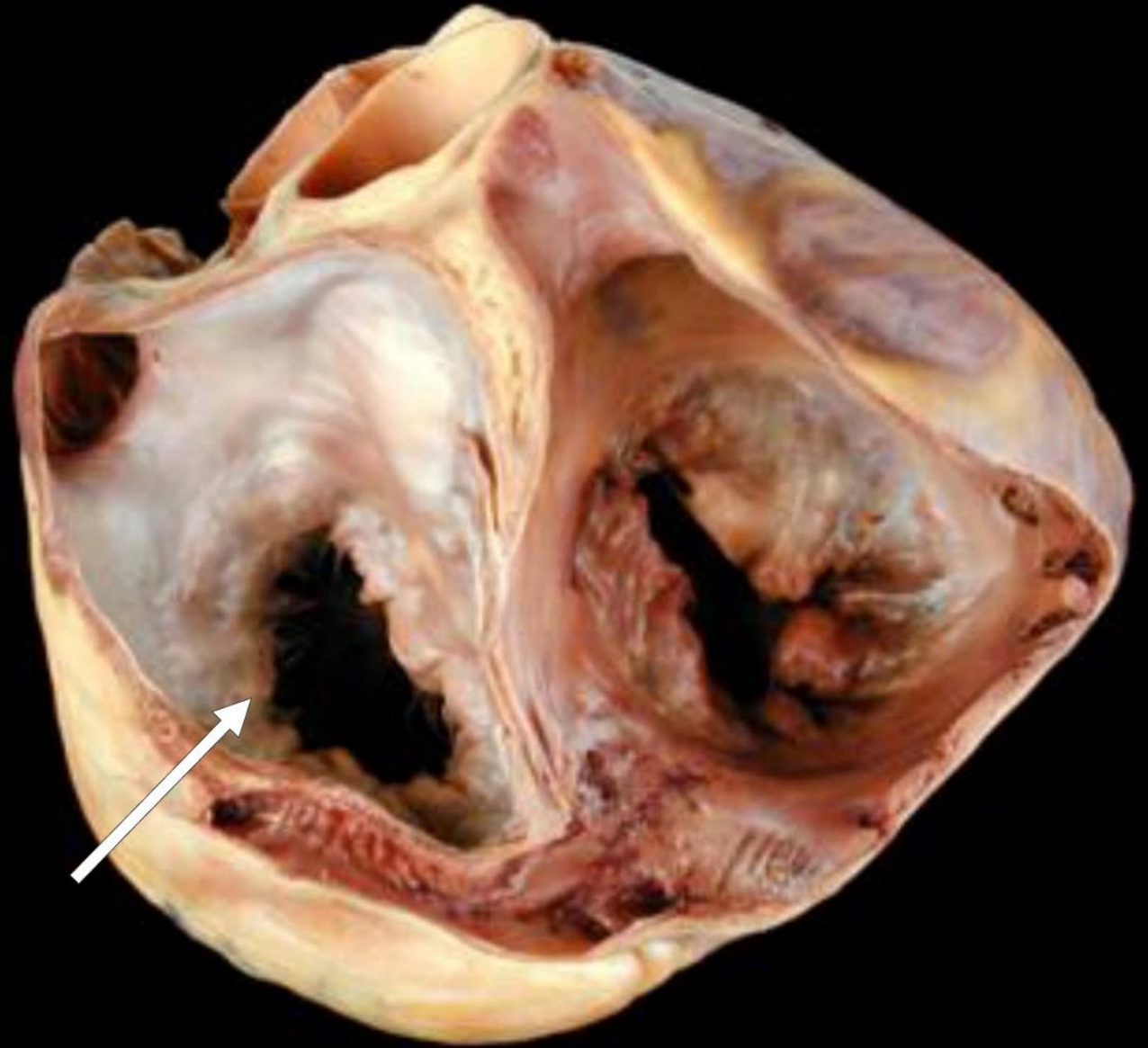
Mitral Orifice



Anterior Cusp of The Mitral Valve

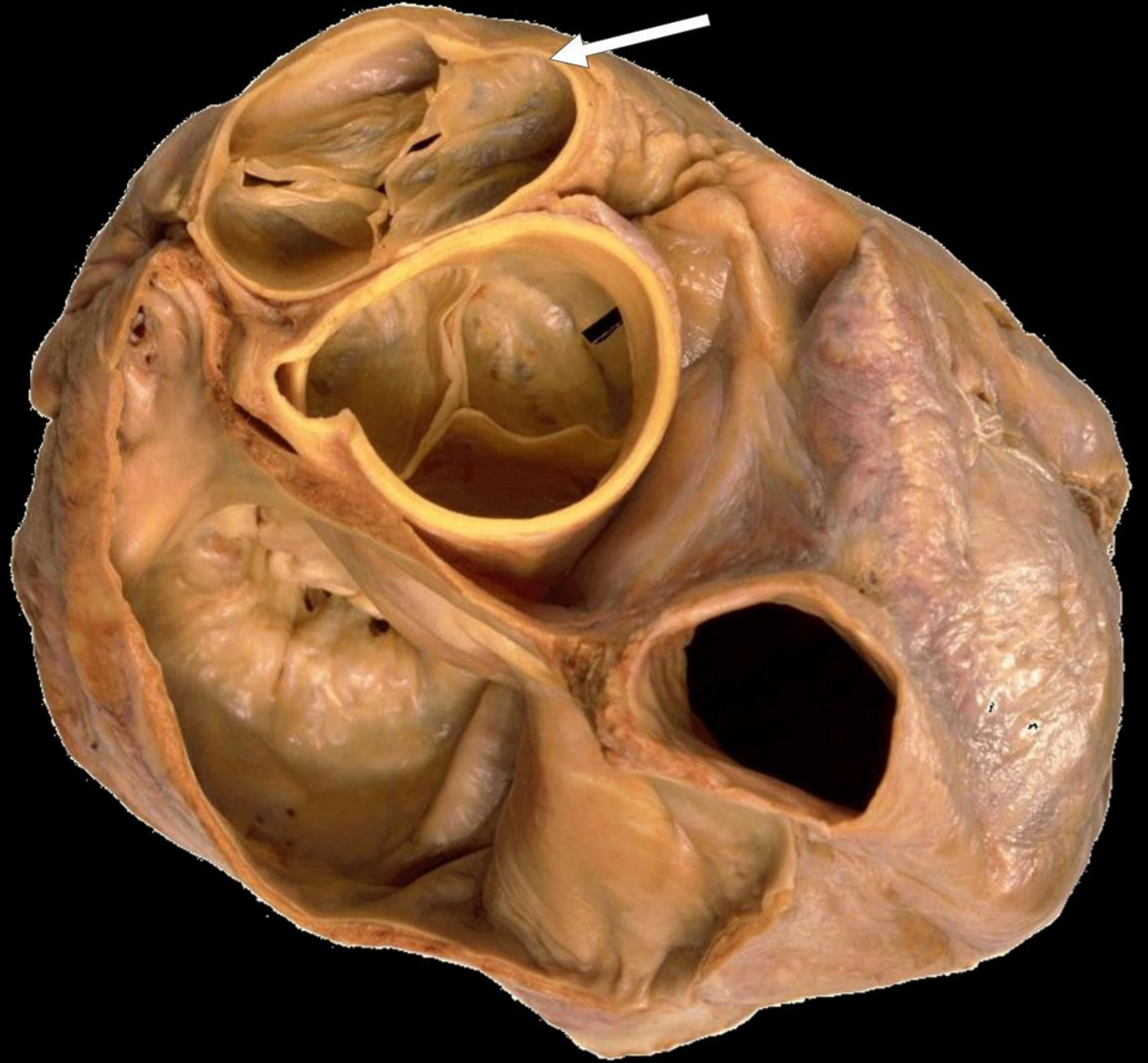


Posterior Cusp of The Mitral Valve

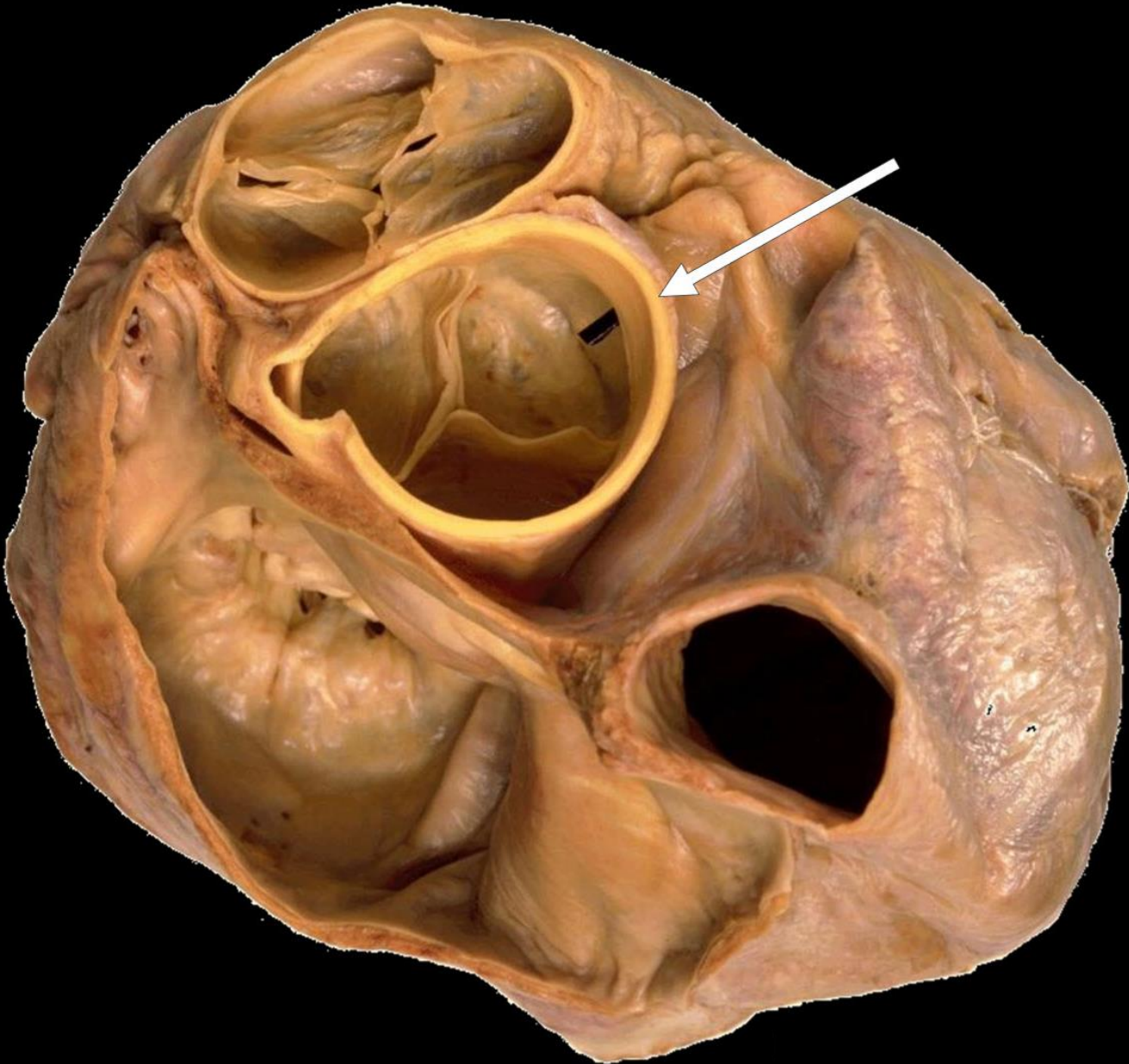


a top view of the semilunar valve

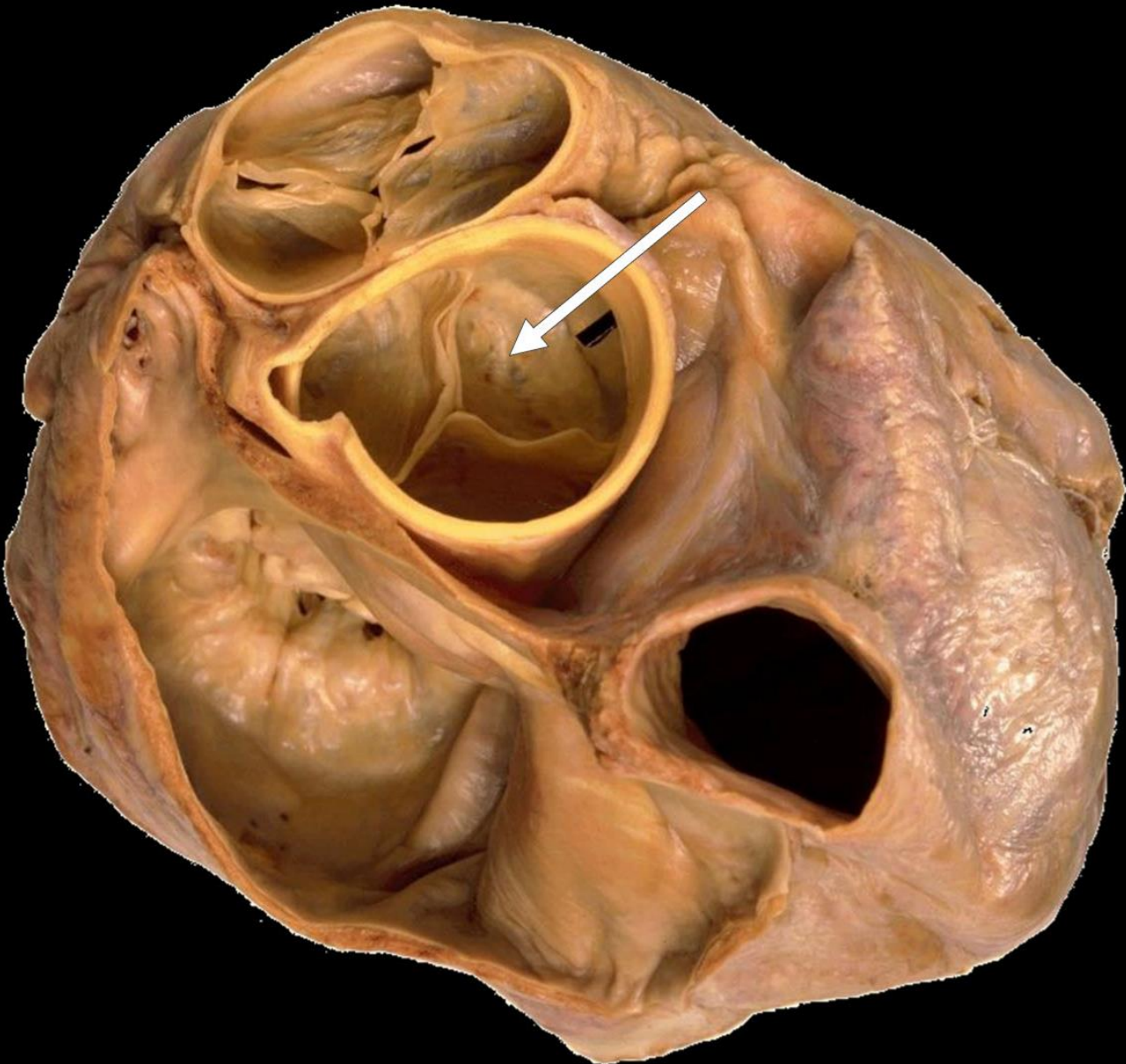
Pulmonary Artery



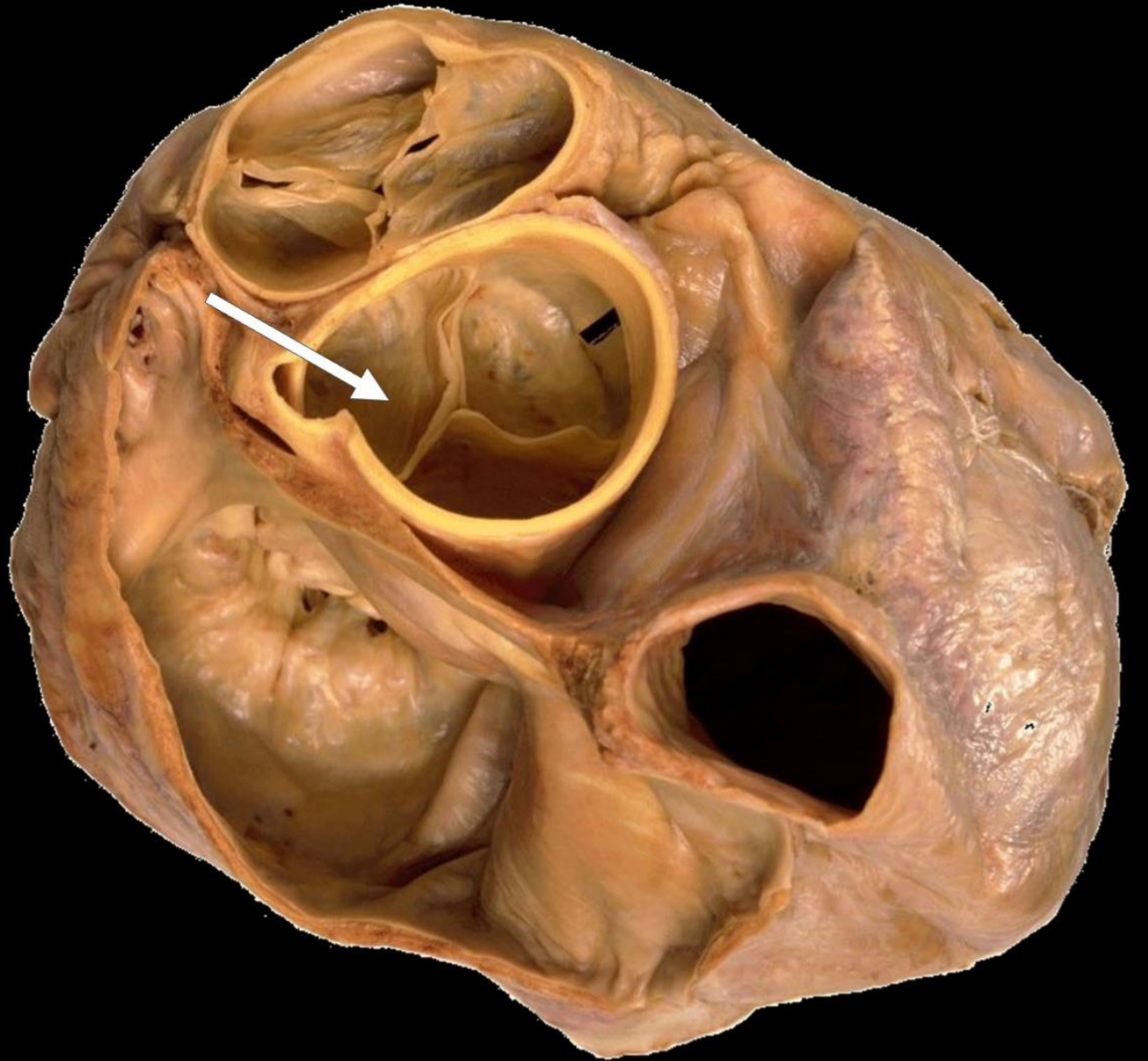
Ascending Aorta



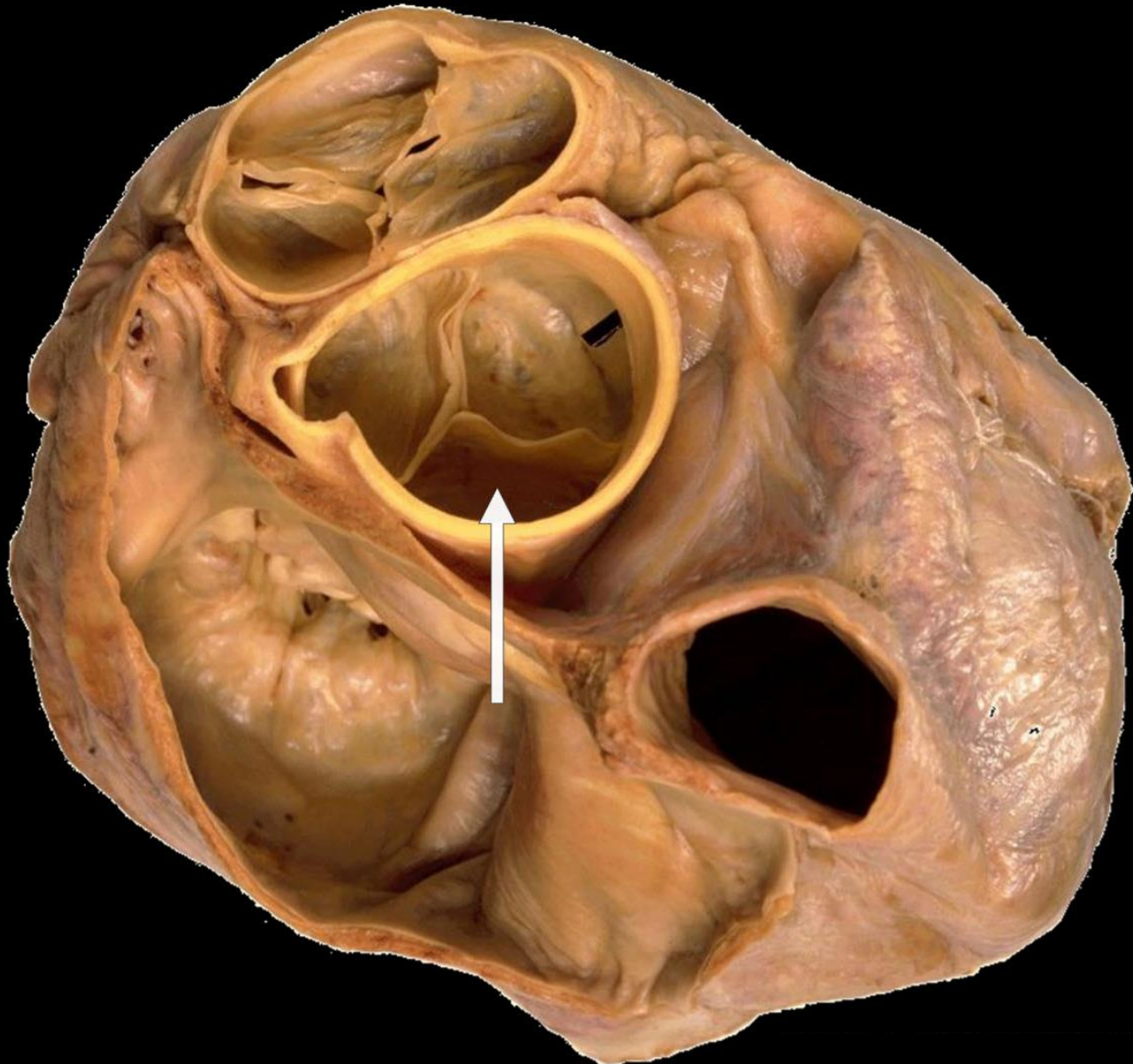
Anterior Aortic
Cusp



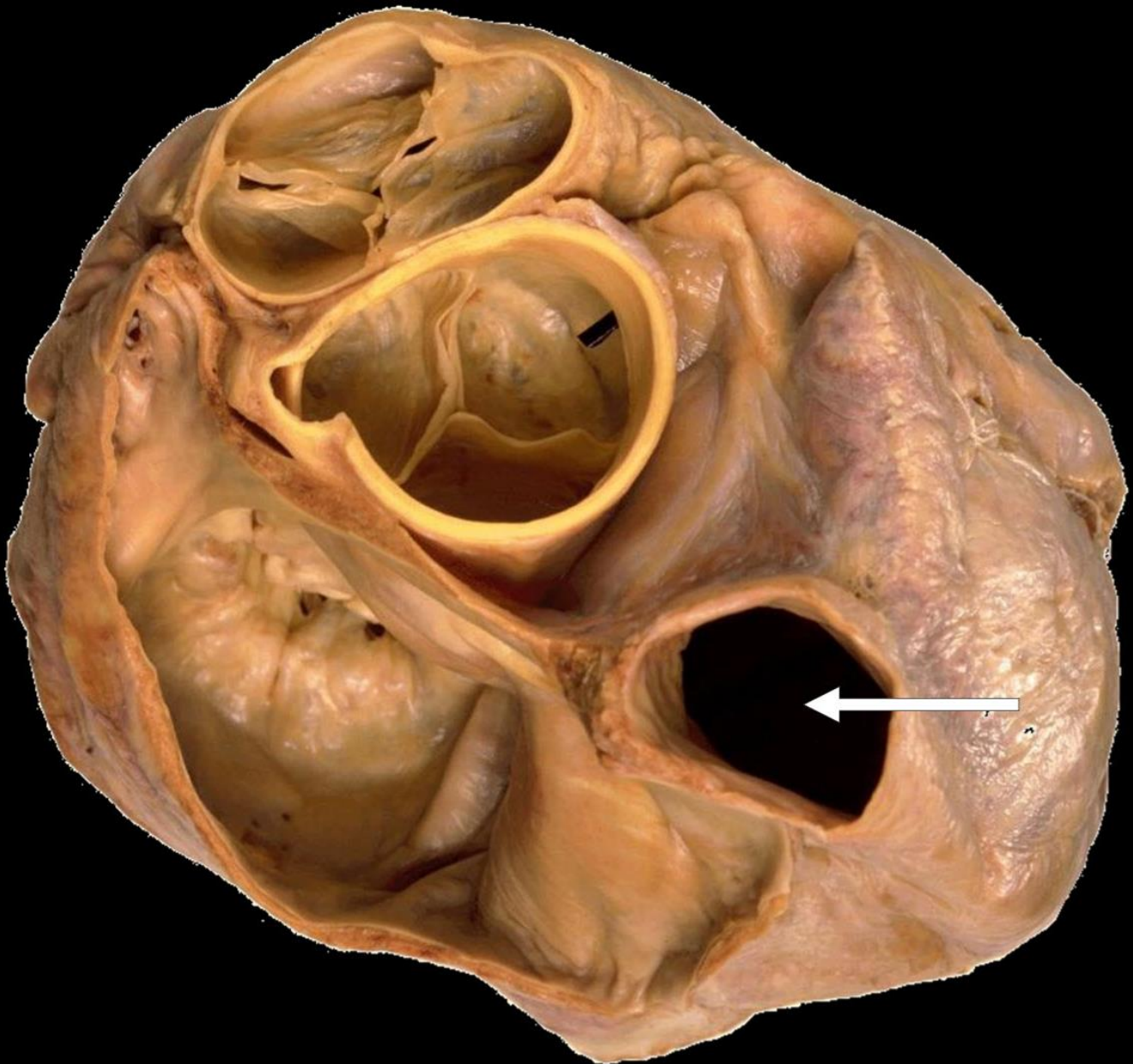
Left Posterior Aortic
Cusp



Right Posterior
Aortic Cusp

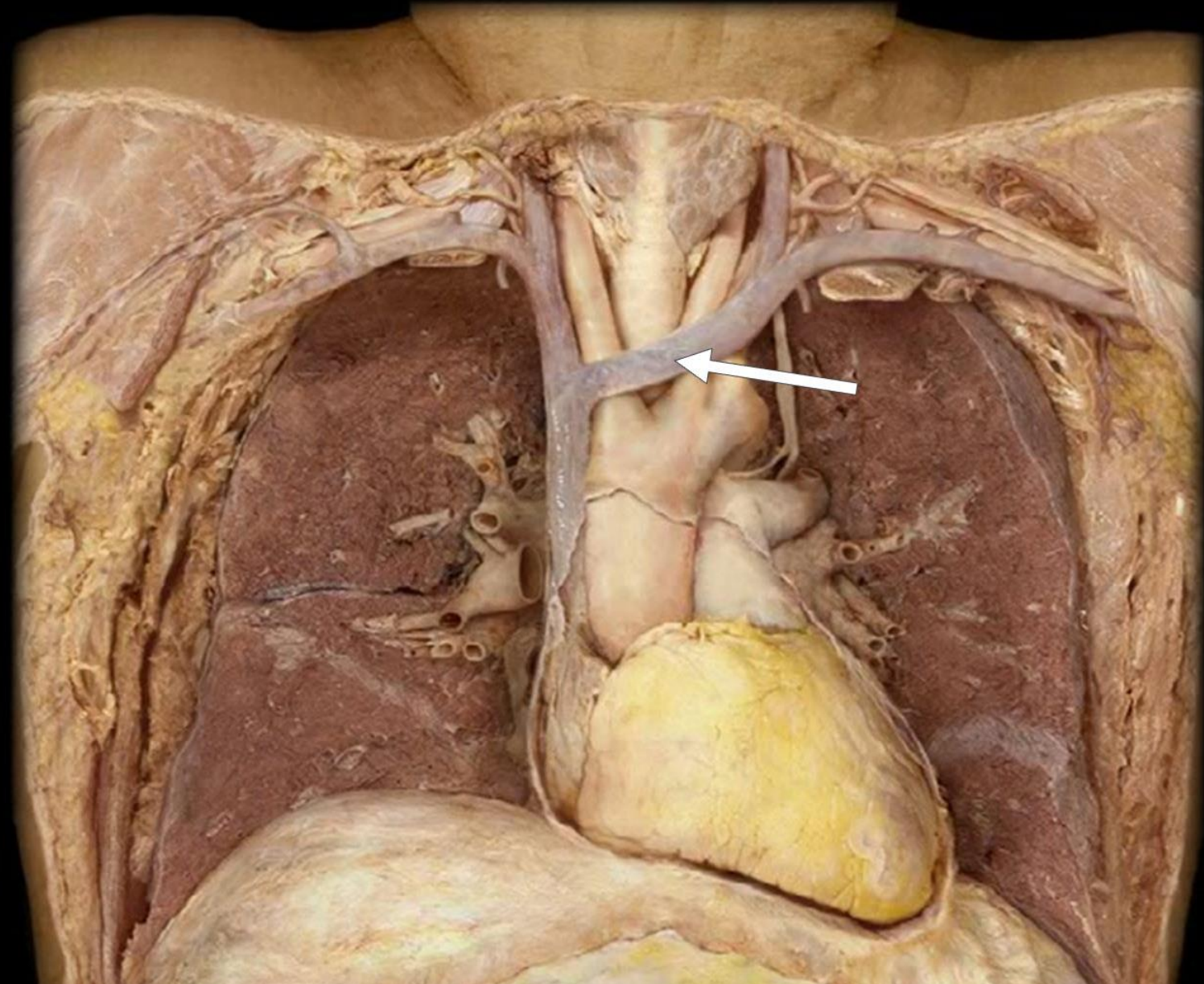


Superior Vena Cav

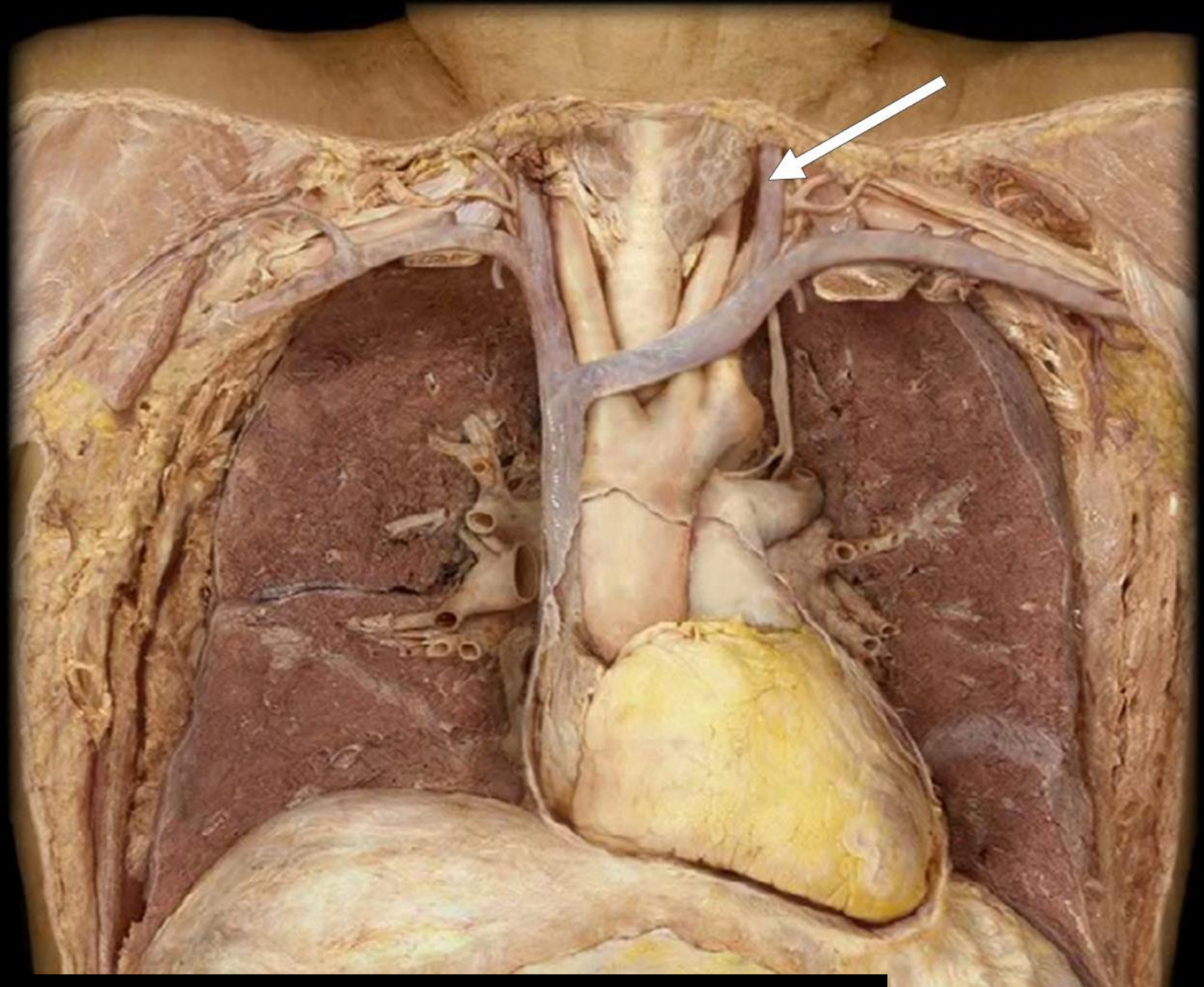


Mediastinum

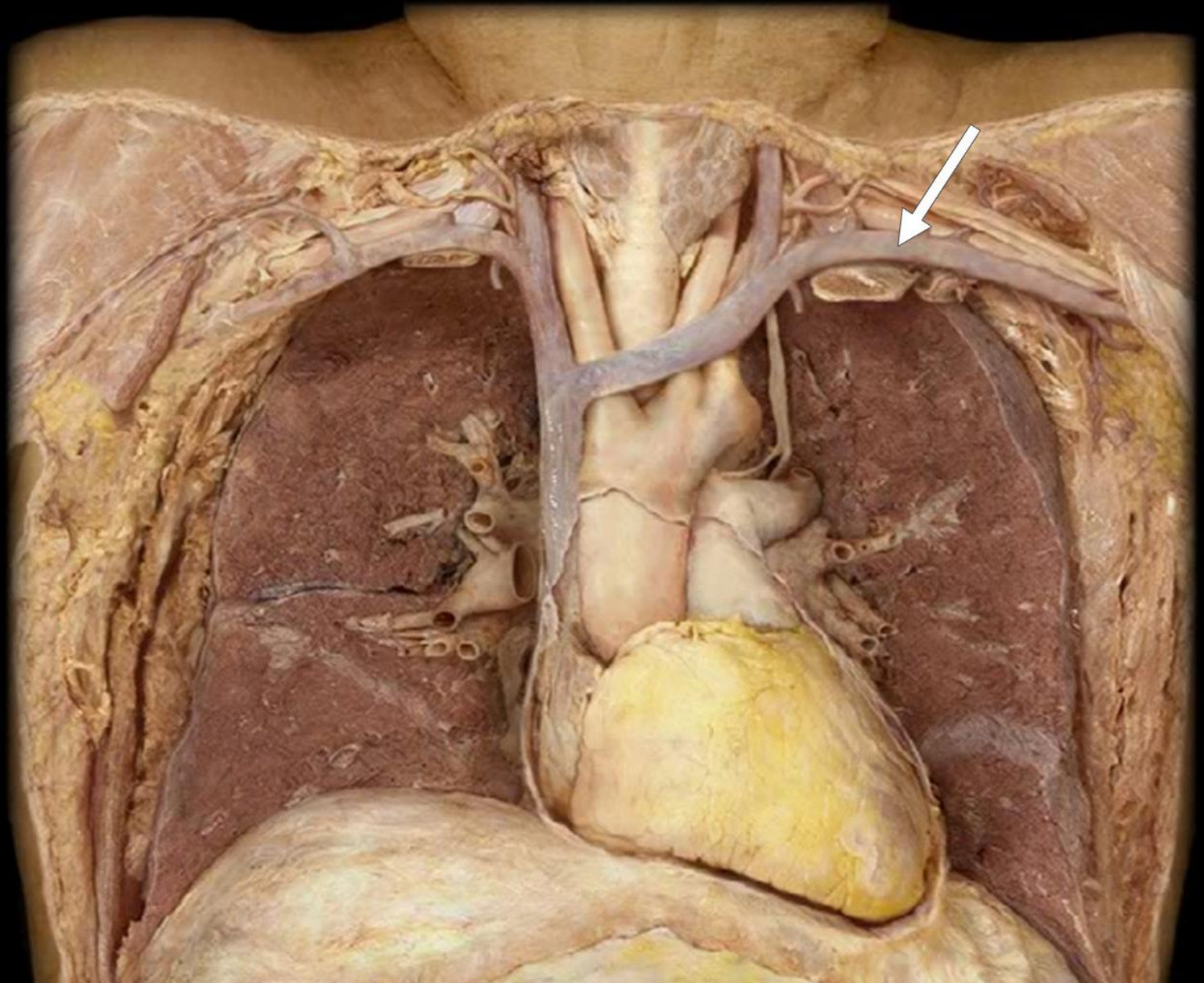
Left
Brachiocephalic
Vein



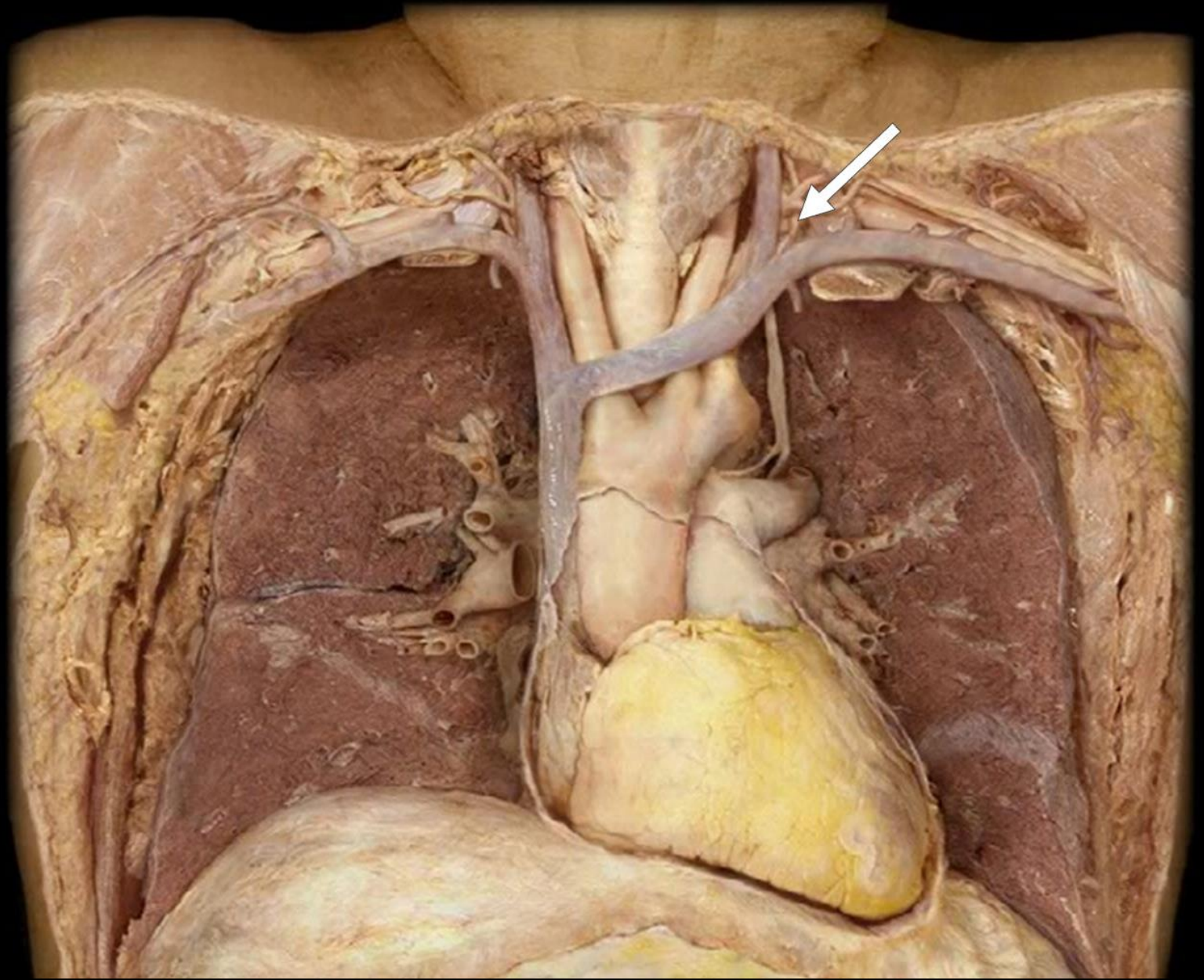
Left Internal
Jugular Vein



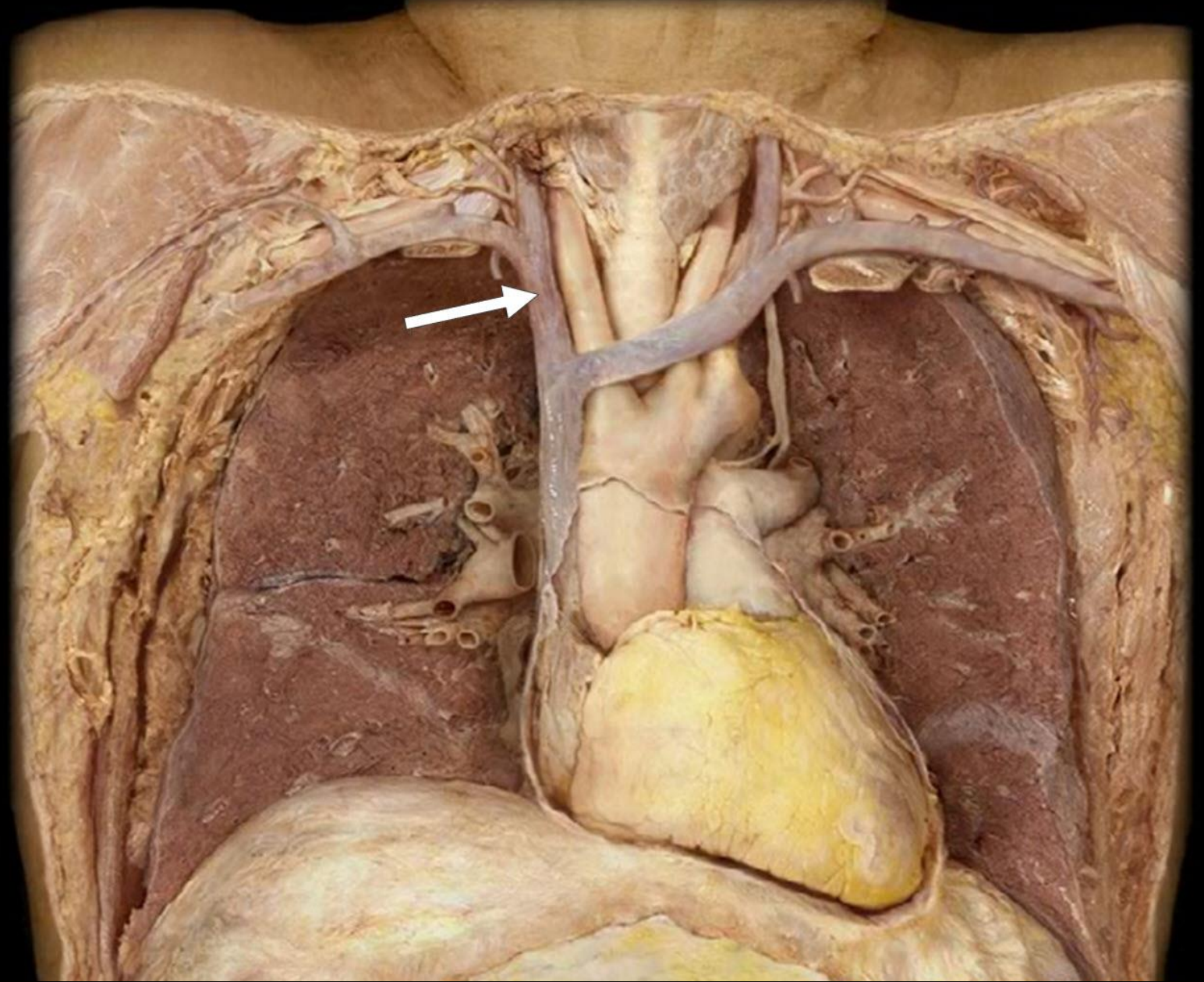
Left Subclavian
Vein



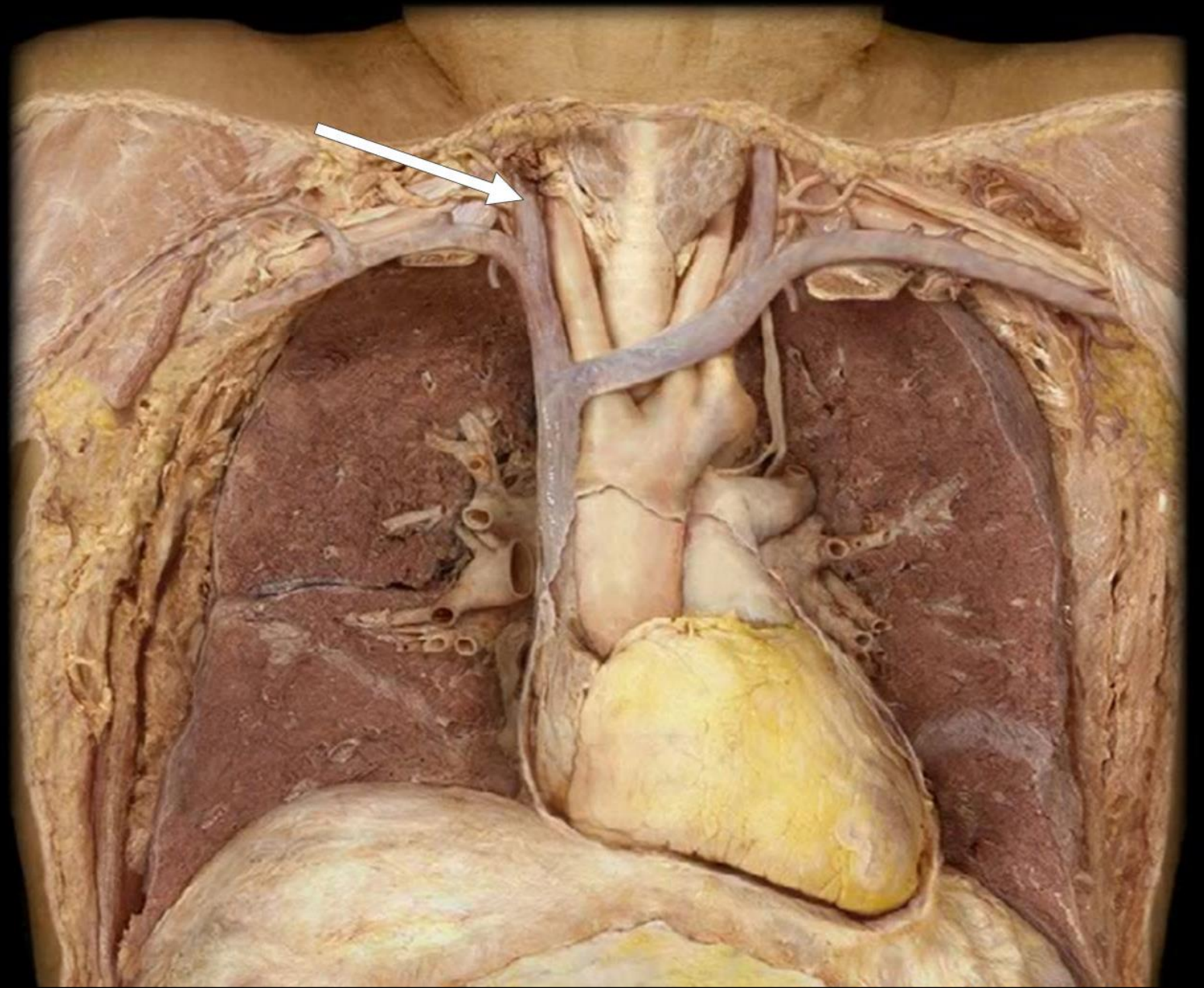
Thoracic Duct



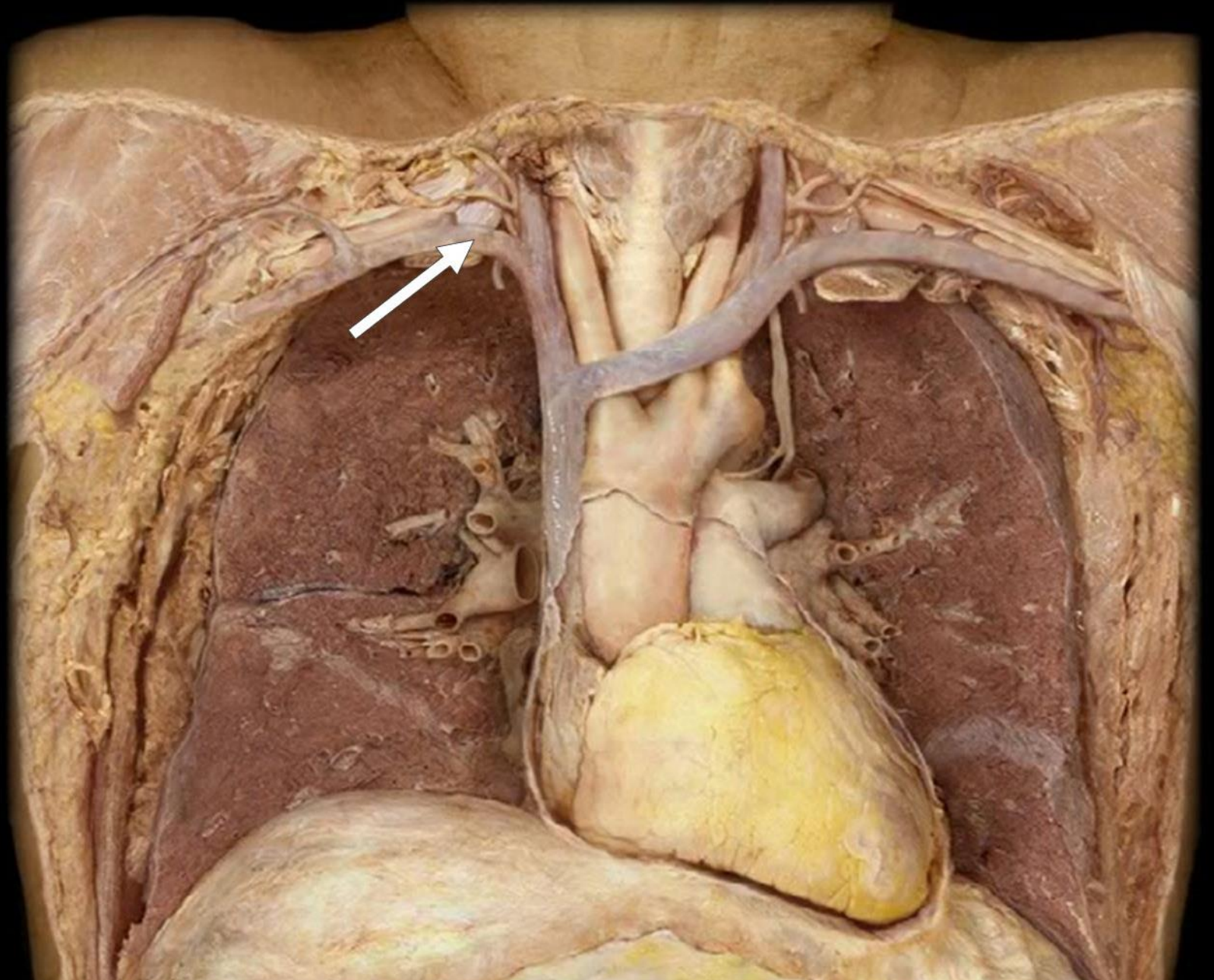
Right
Brachiocephalic
Vein



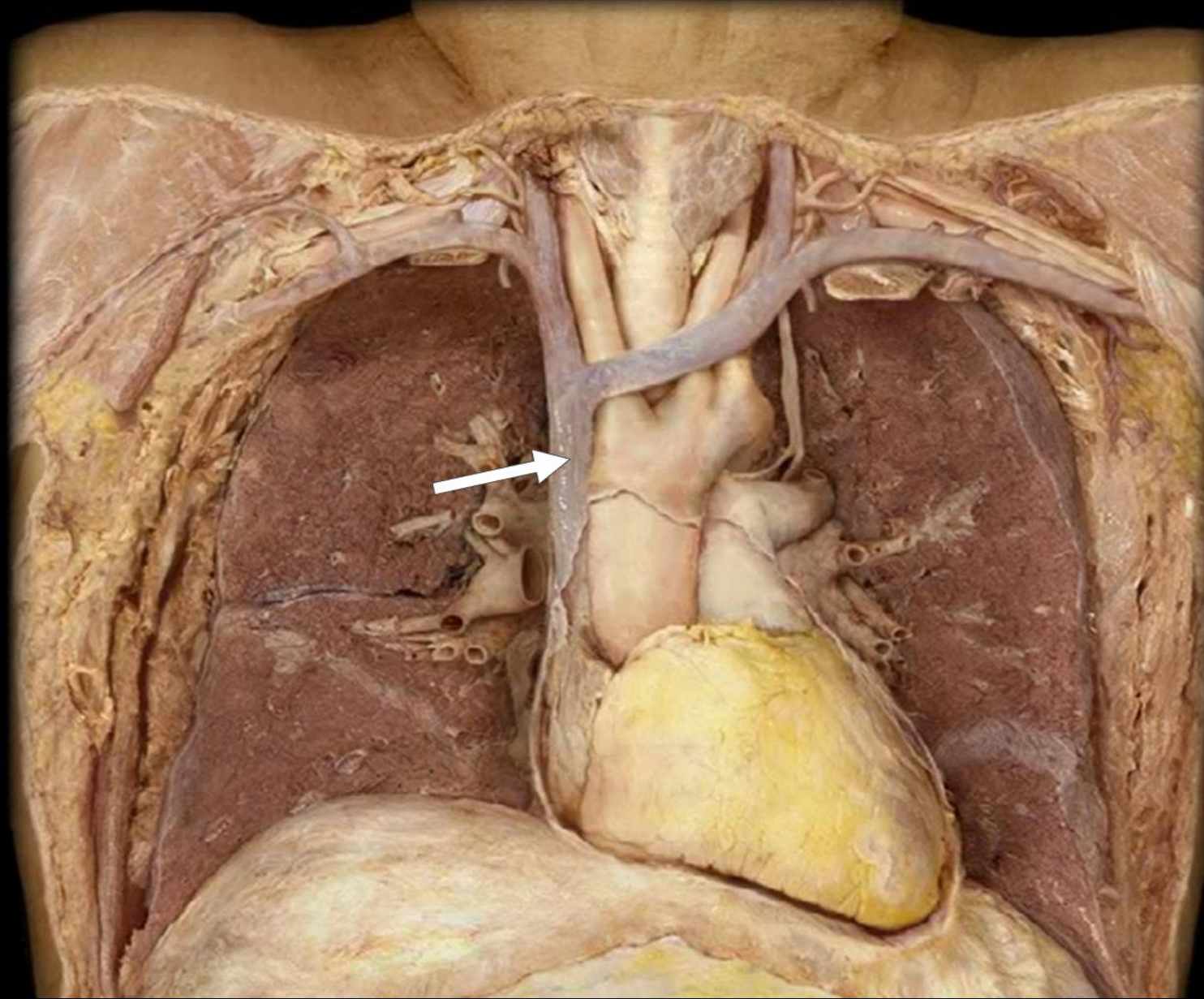
Right Internal
Jugular Vein



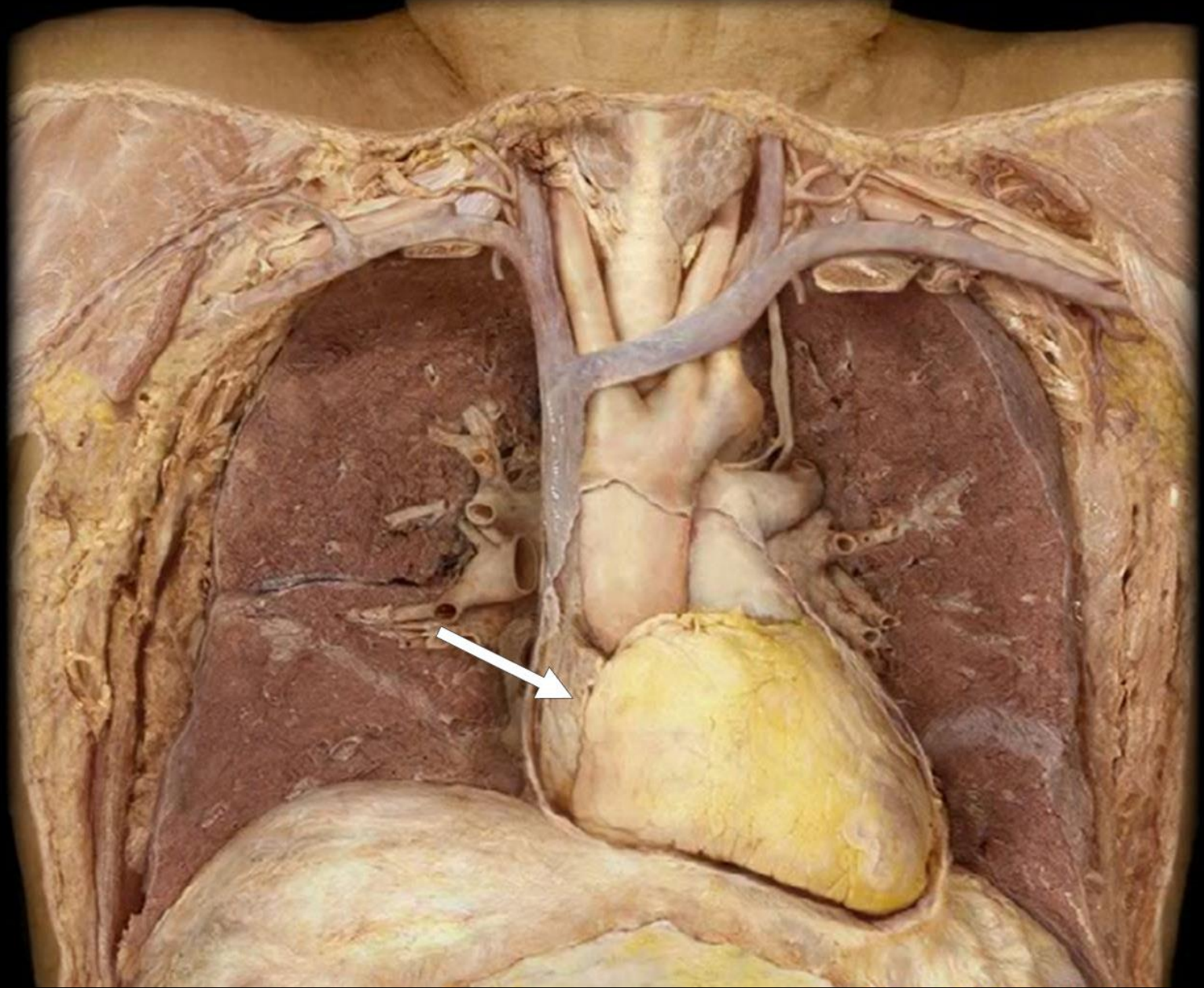
Right
Subclavian Vein



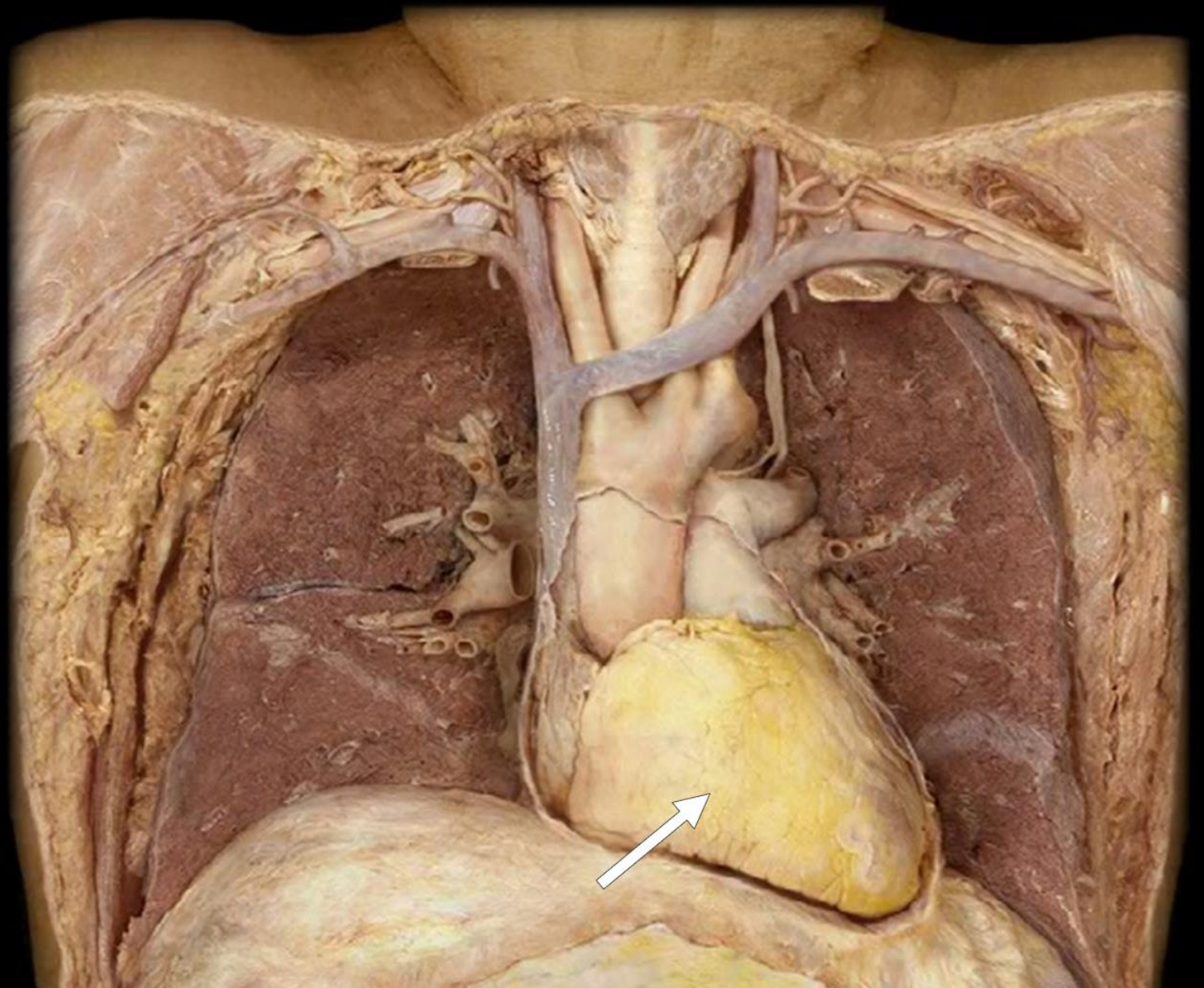
Superior Vena Cava



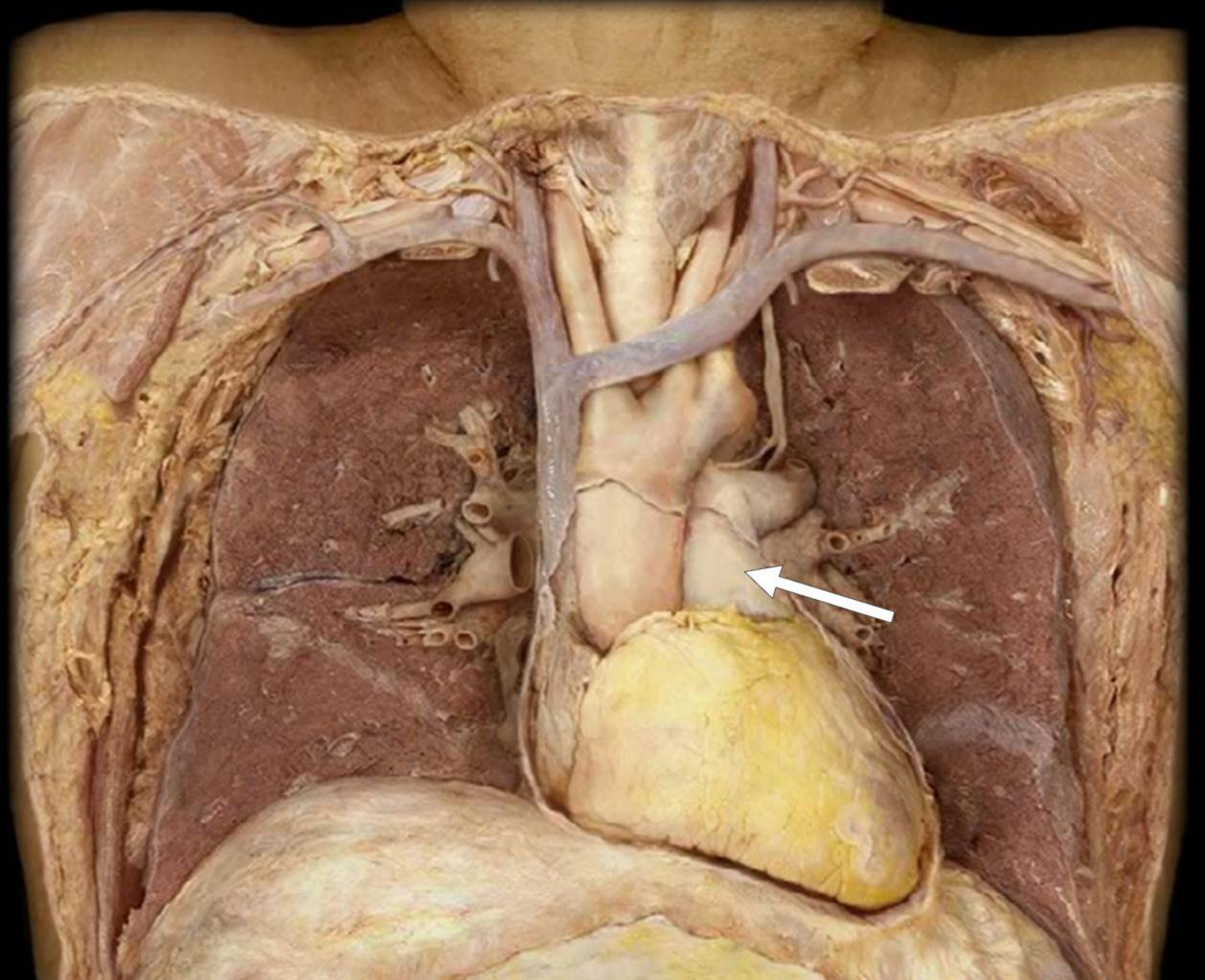
Right Atrium



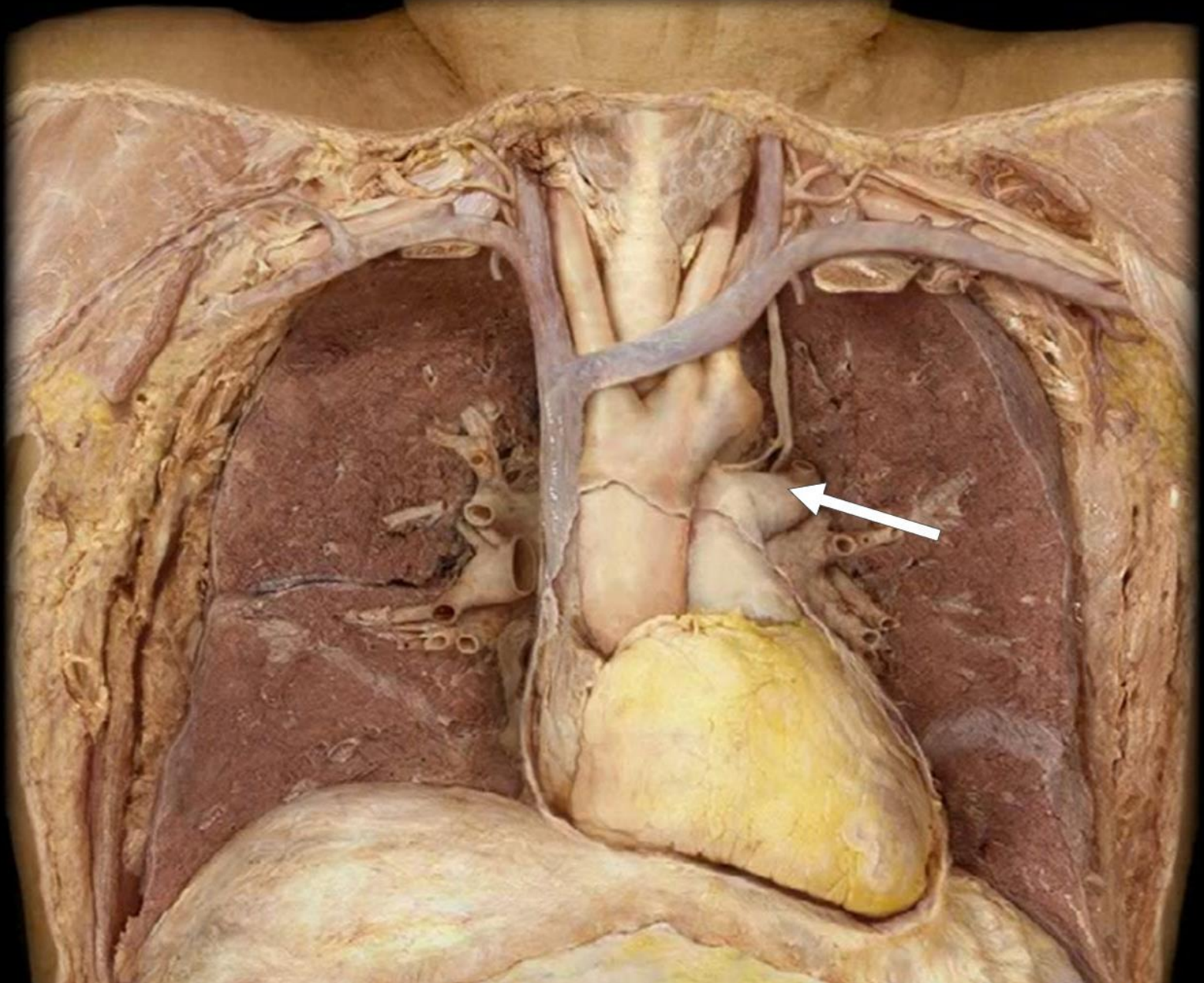
Right Ventricle



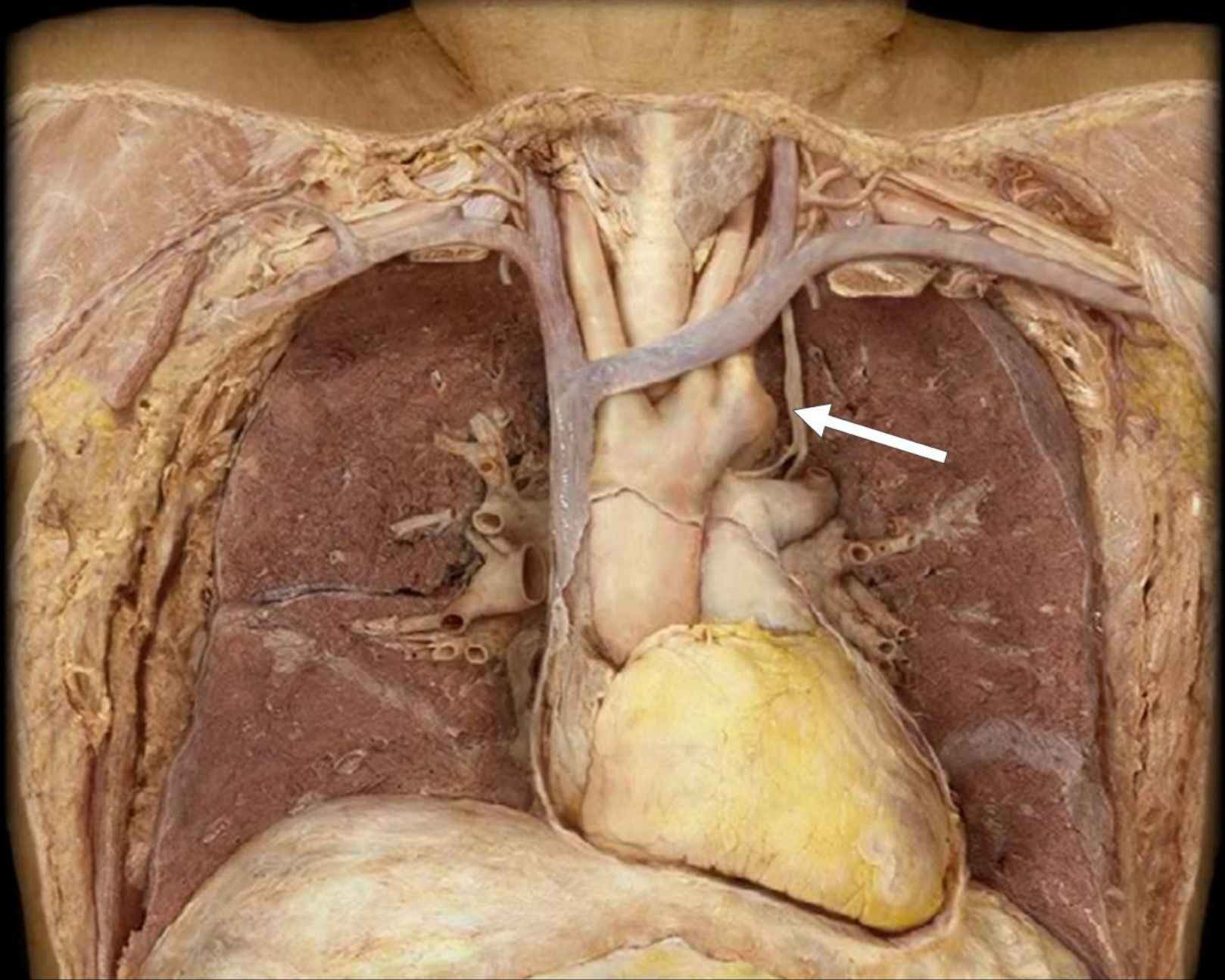
Pulmonary Trunk



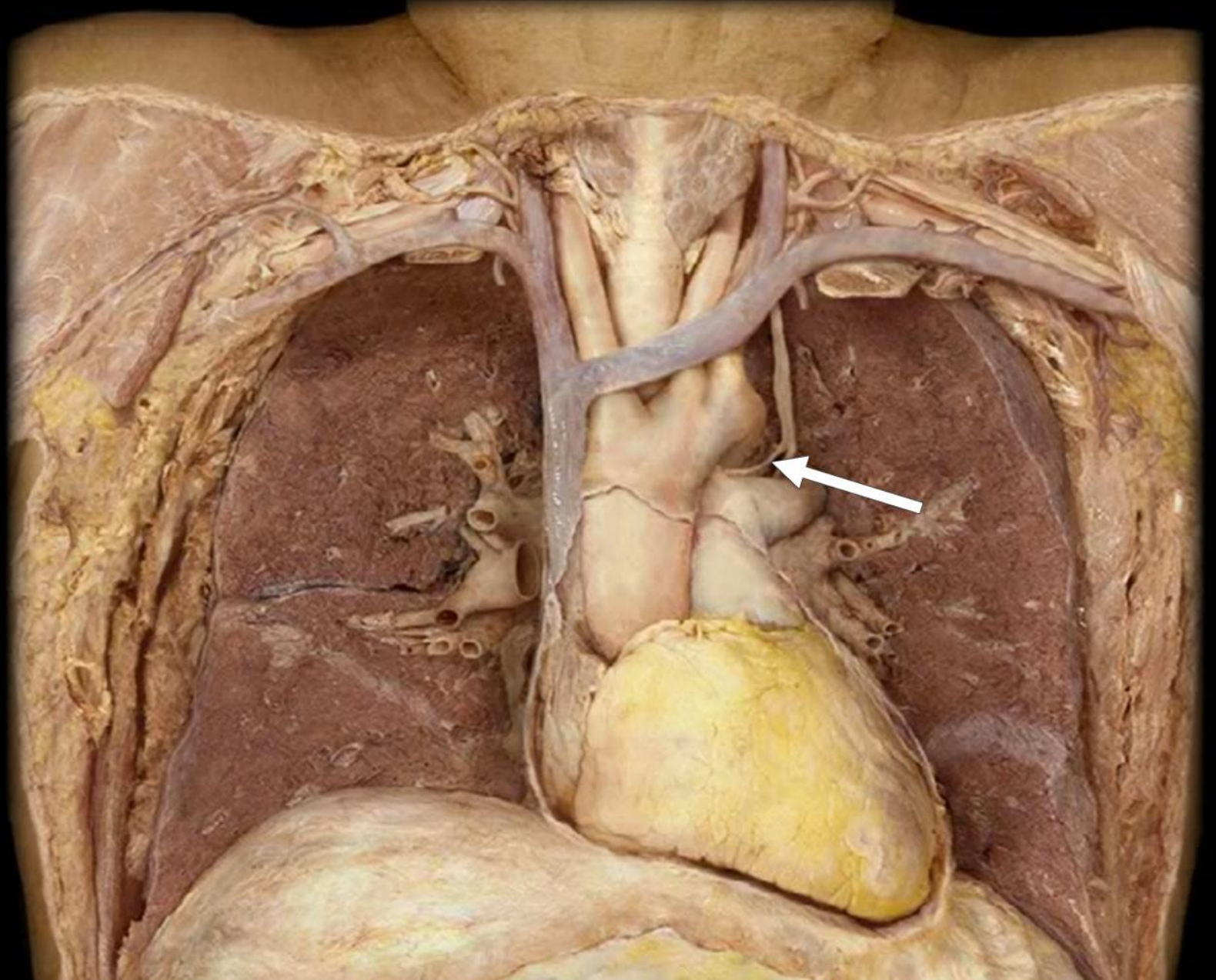
Left Pulmonary



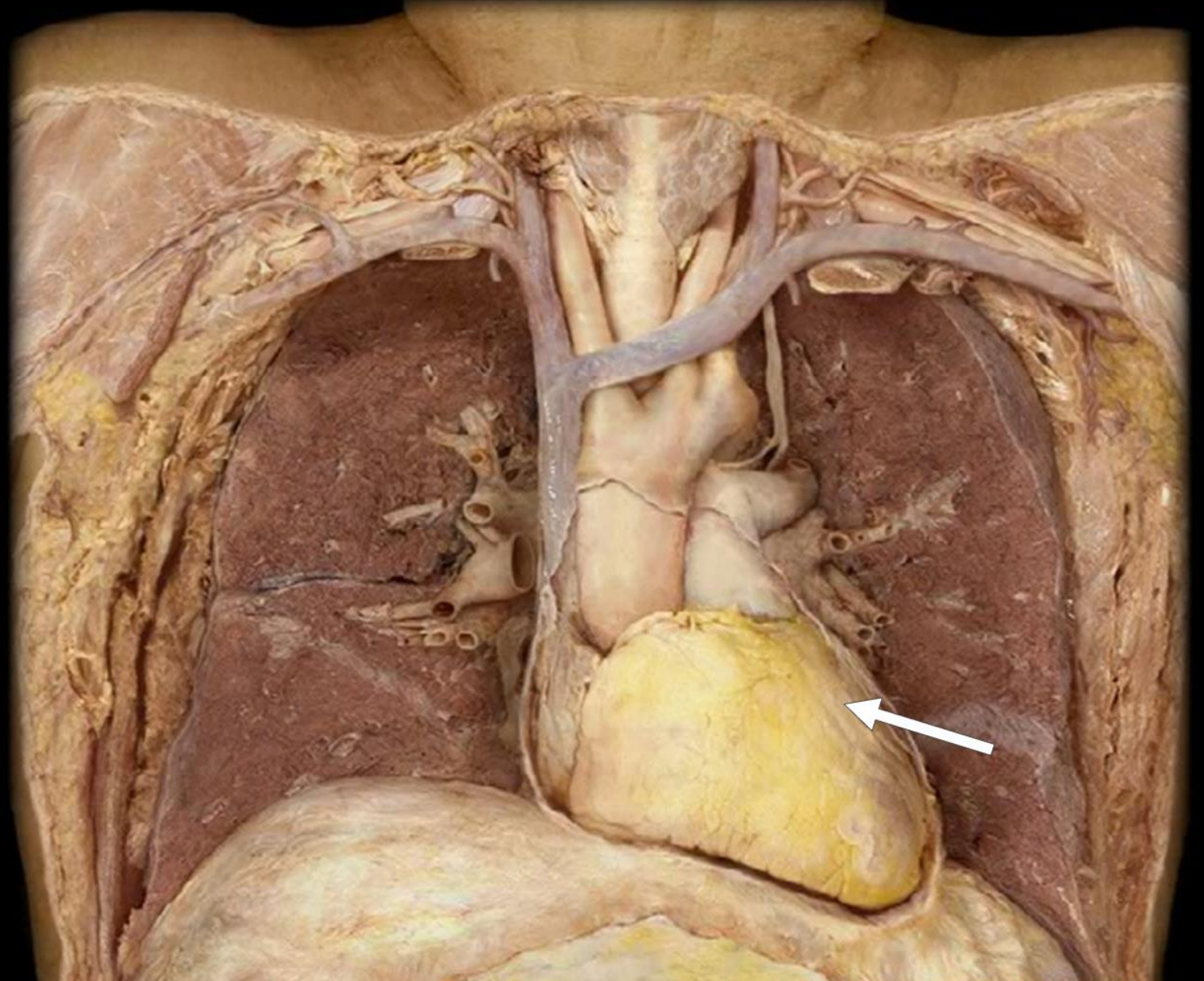
Left Vagus Nerve



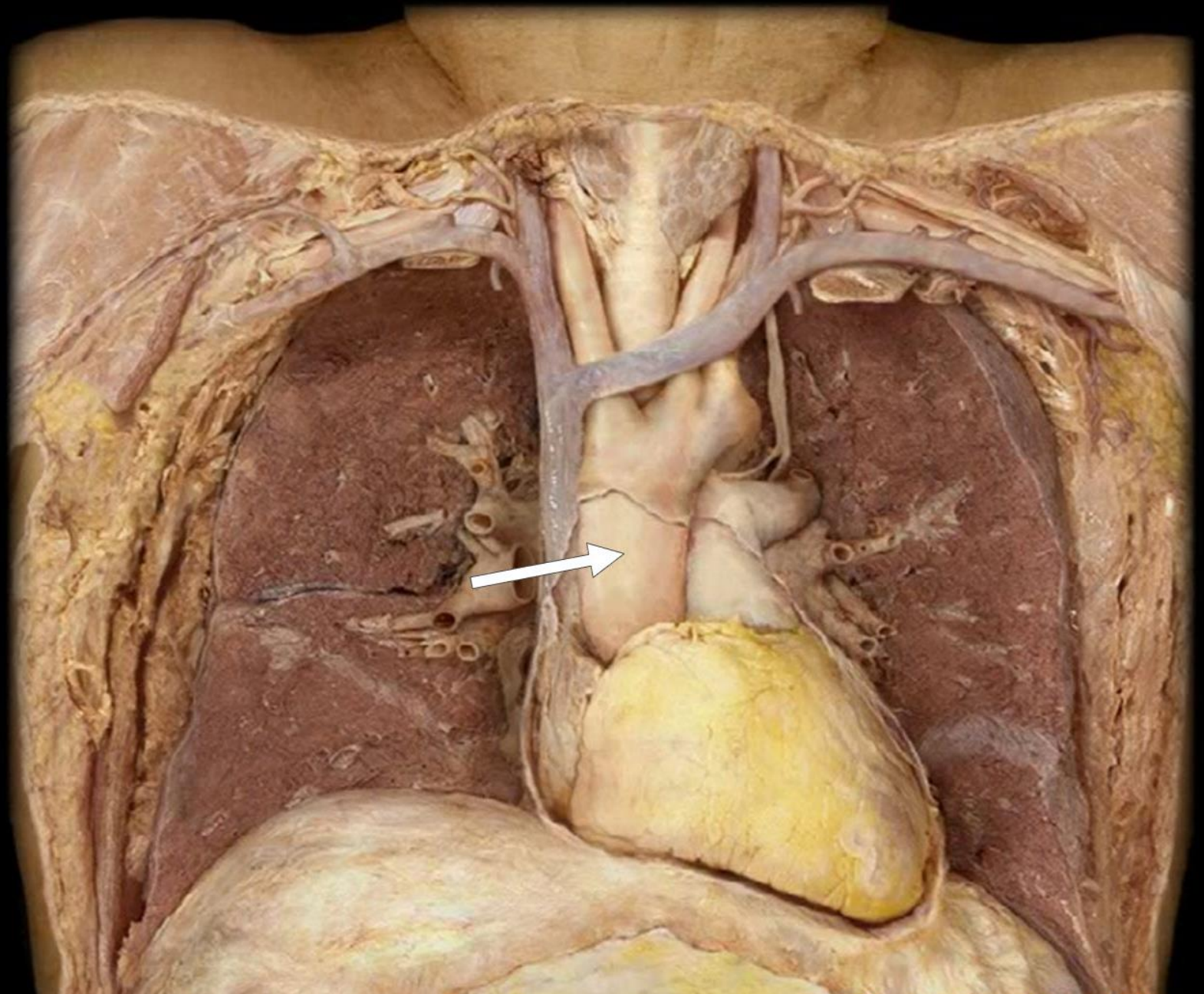
Left Recurrent
Laryngeal
Nerve



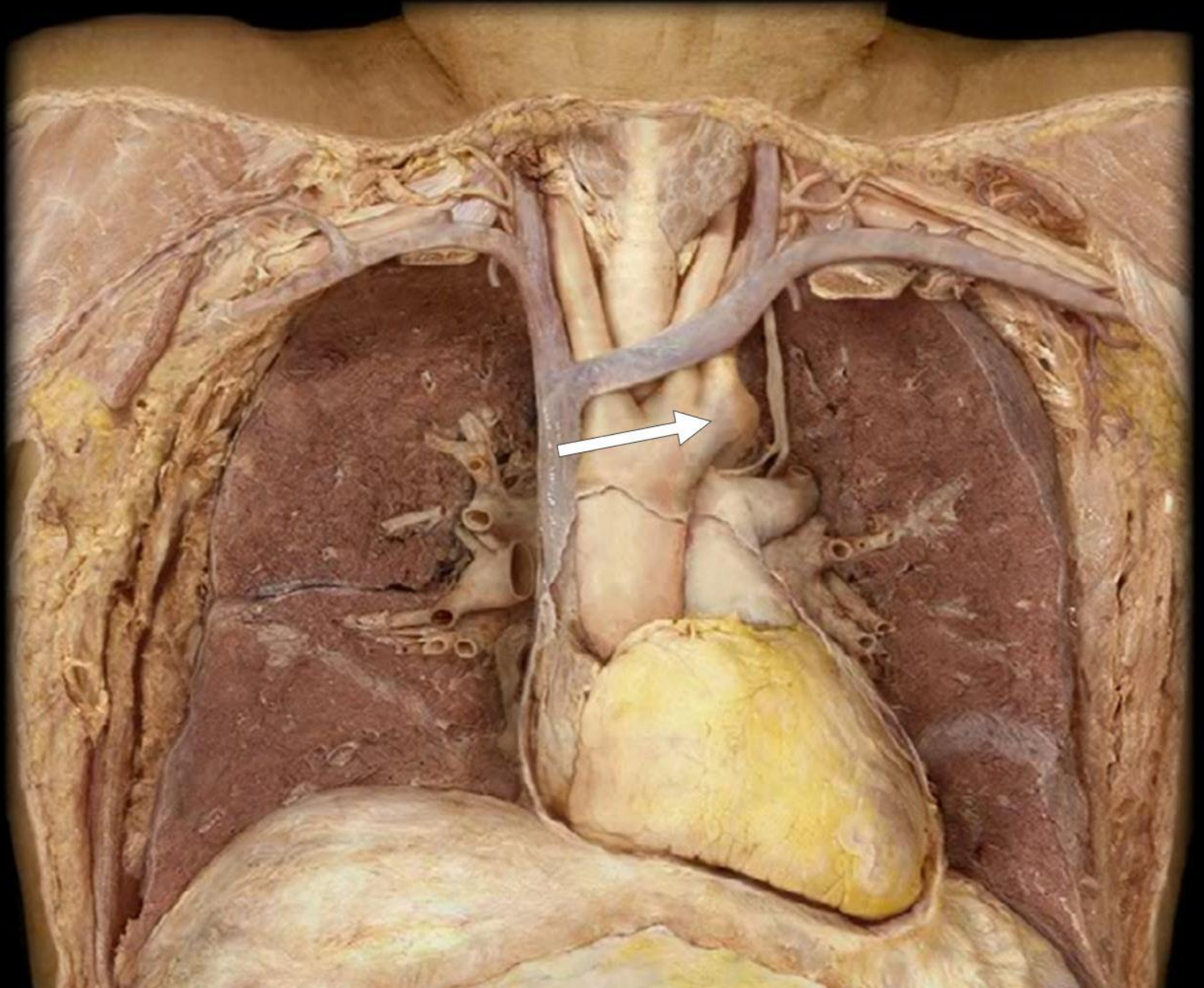
Left Ventricle



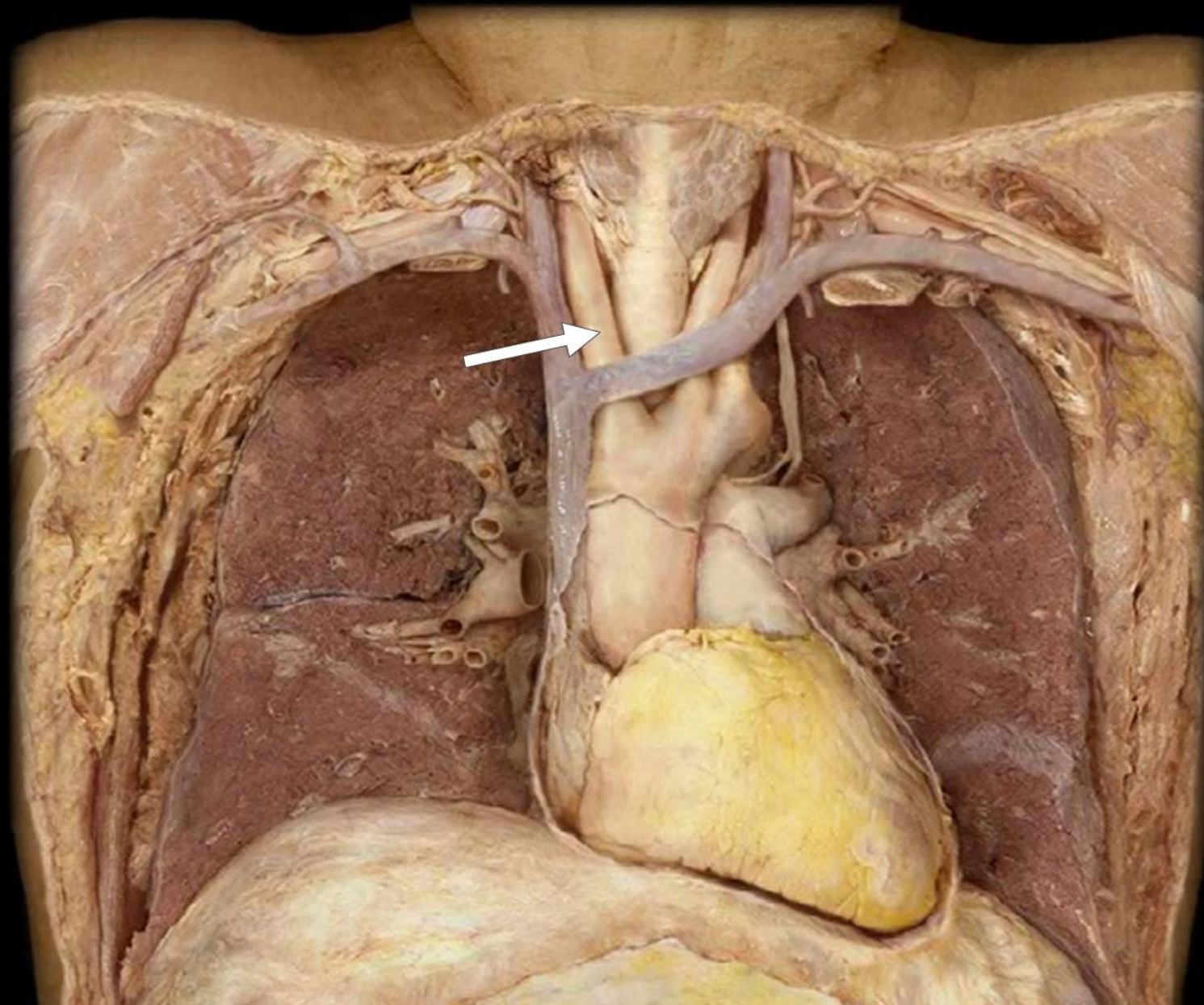
Ascending
Aorta



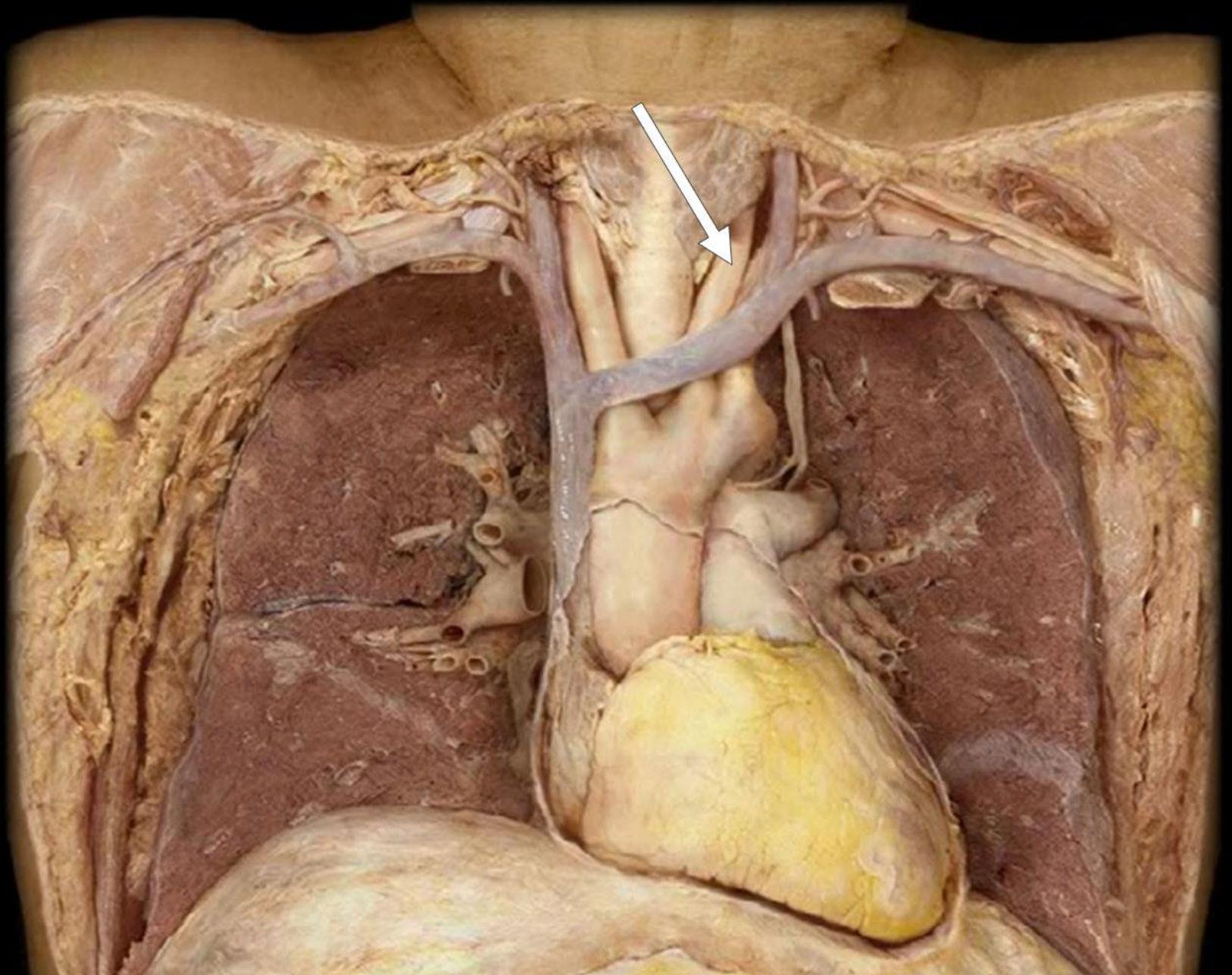
Arch of Aorta



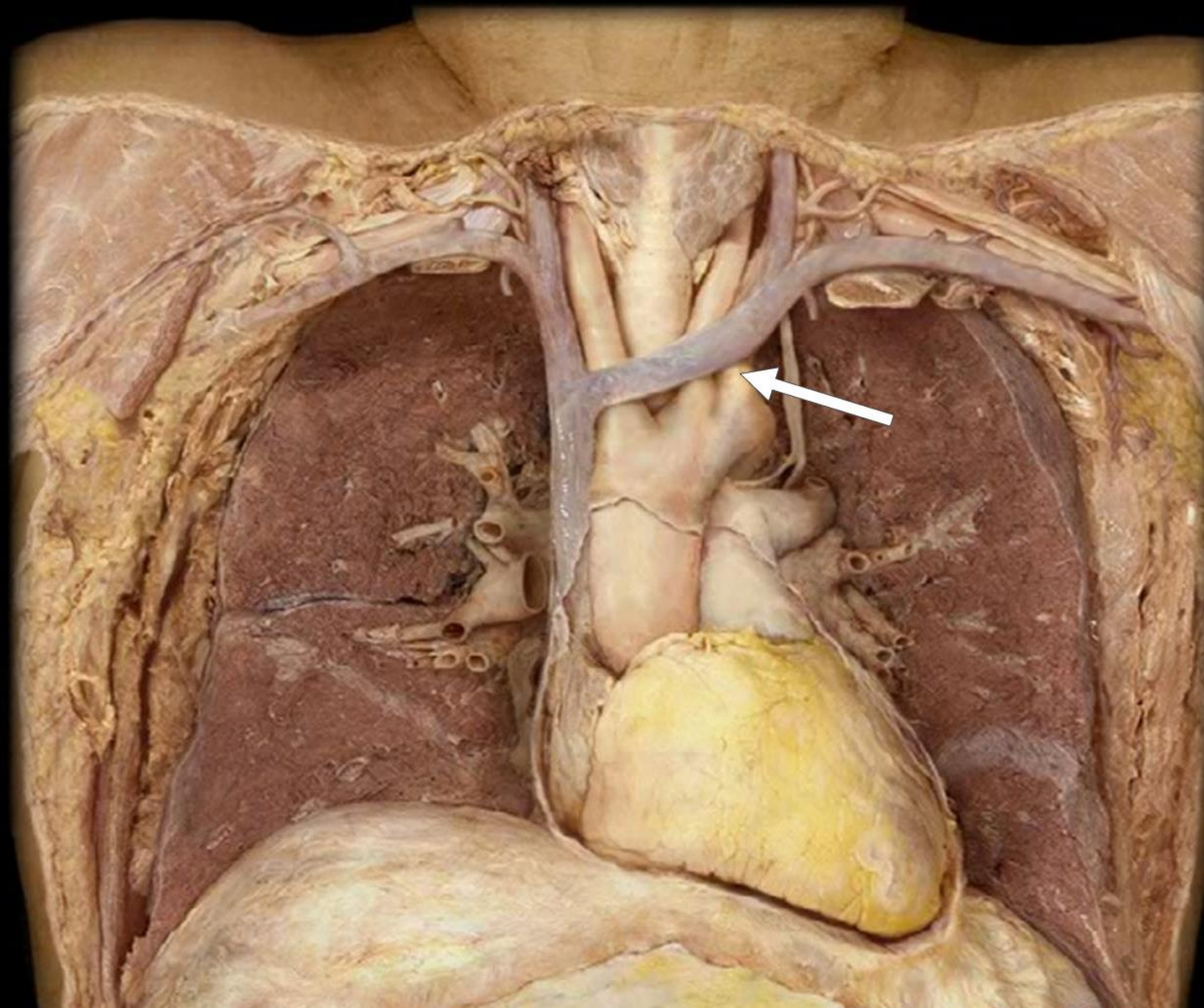
Brachiocephalic Artery



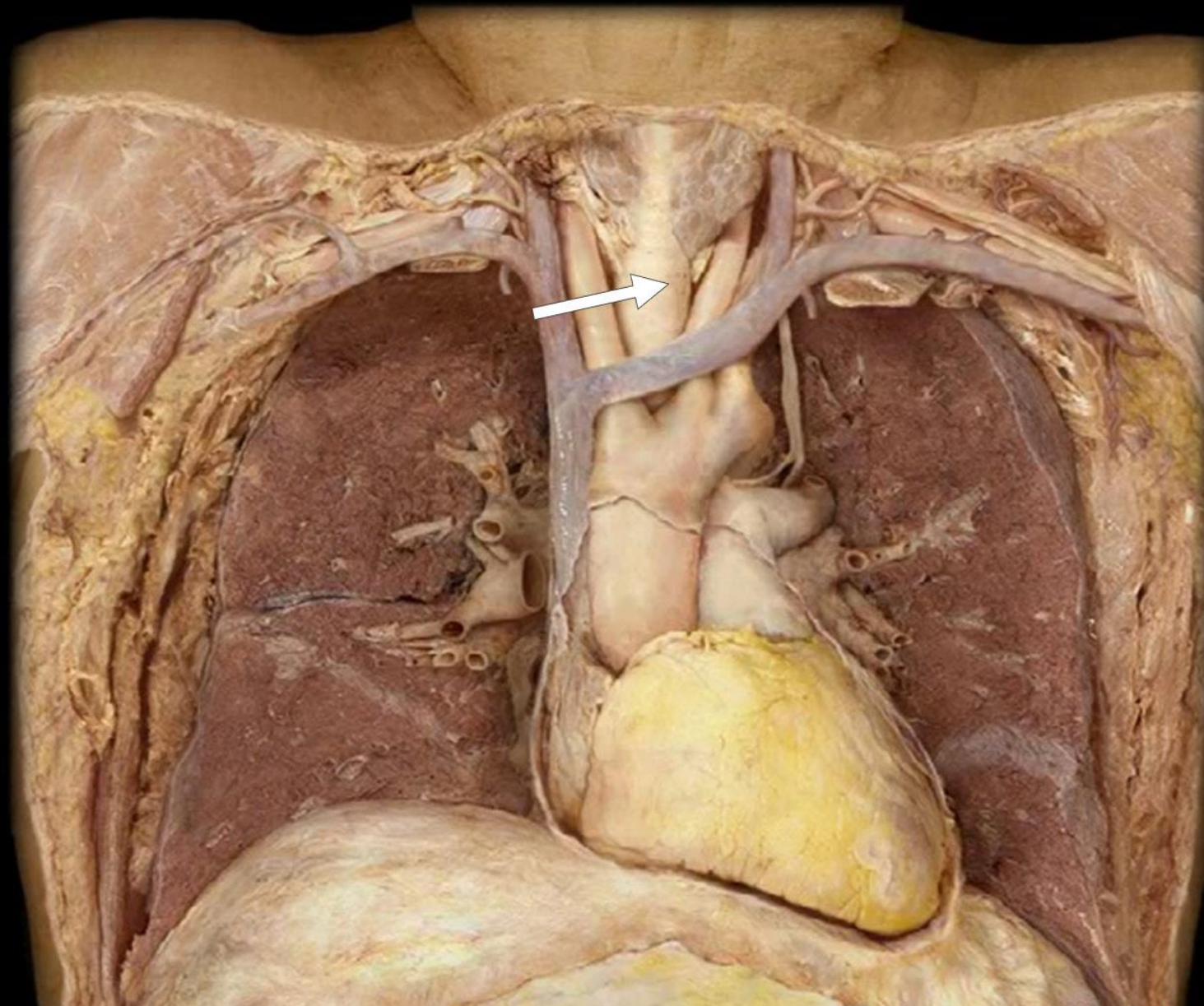
Left Common
Carotid Artery



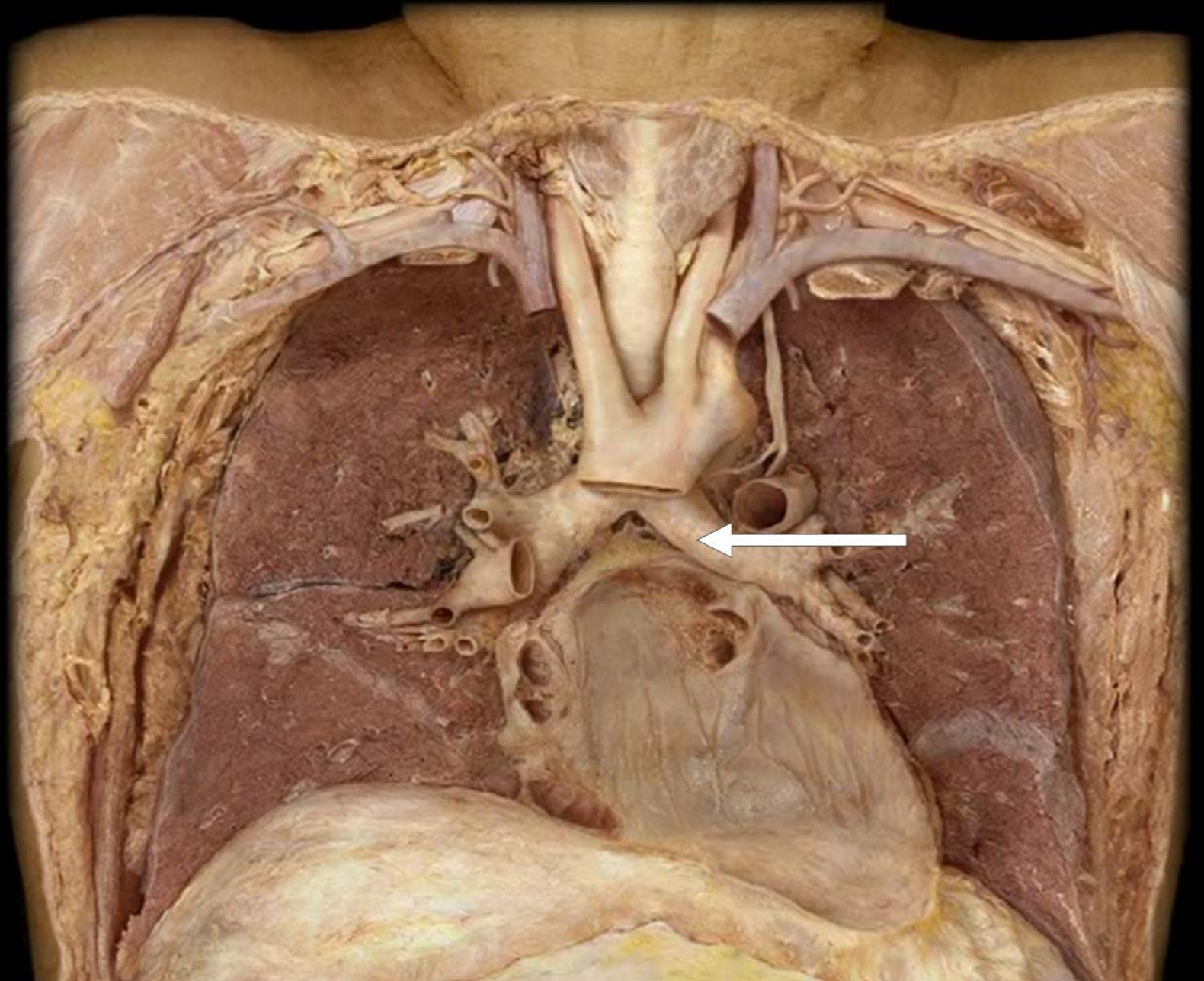
Left Subclavian Artery



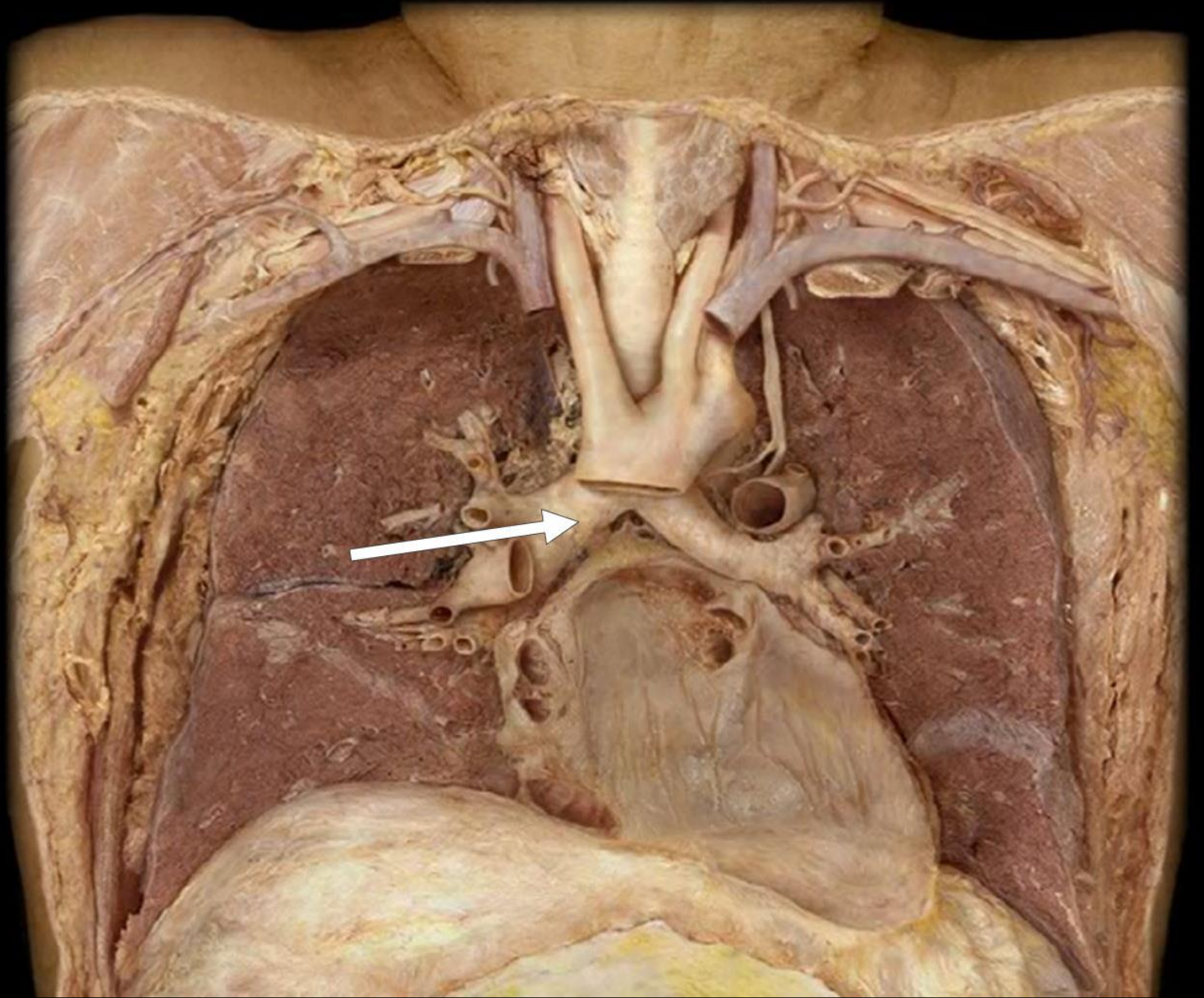
Trachea



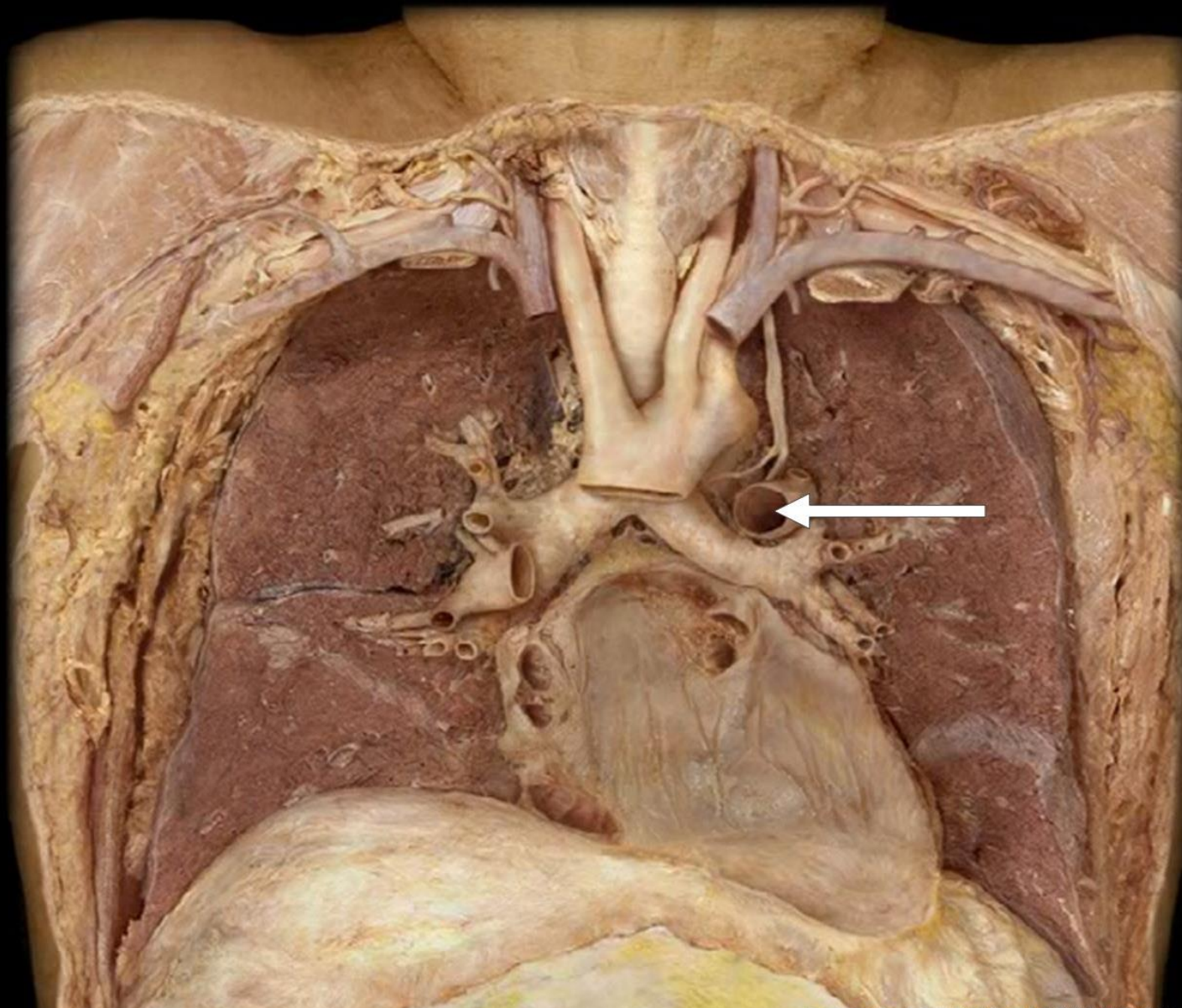
Left Bronchus



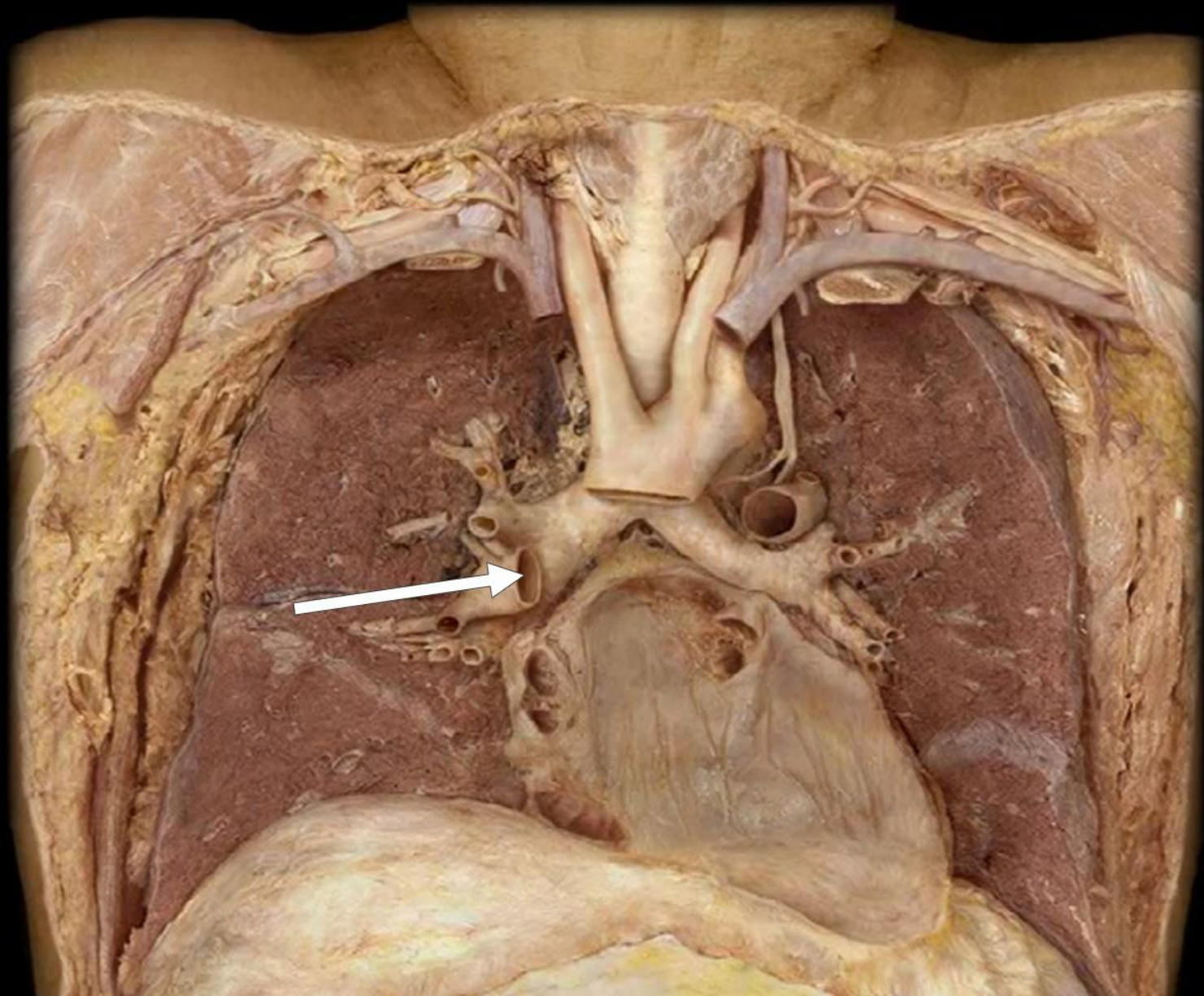
Right Bronchus



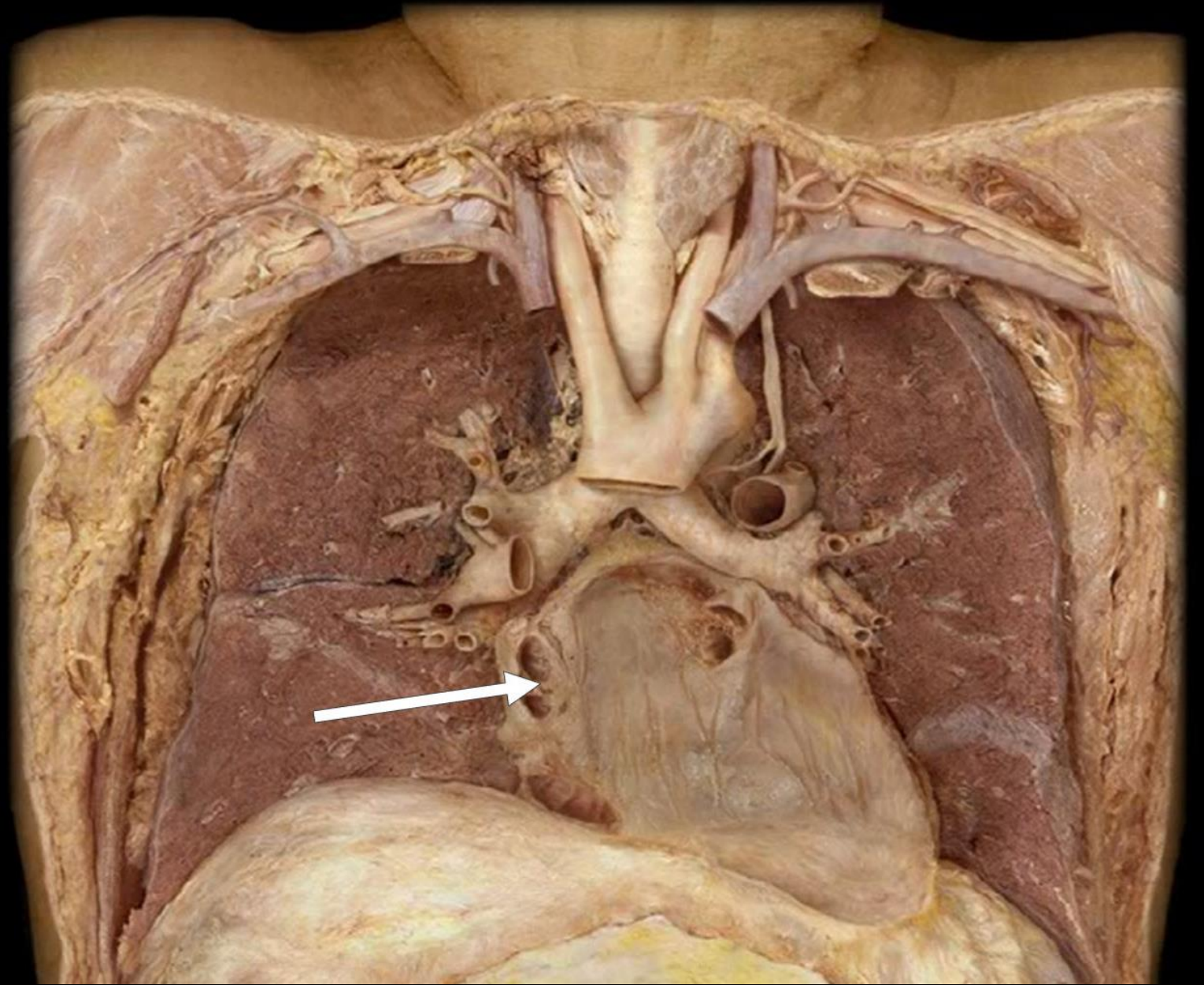
Left Pulmonary Artery



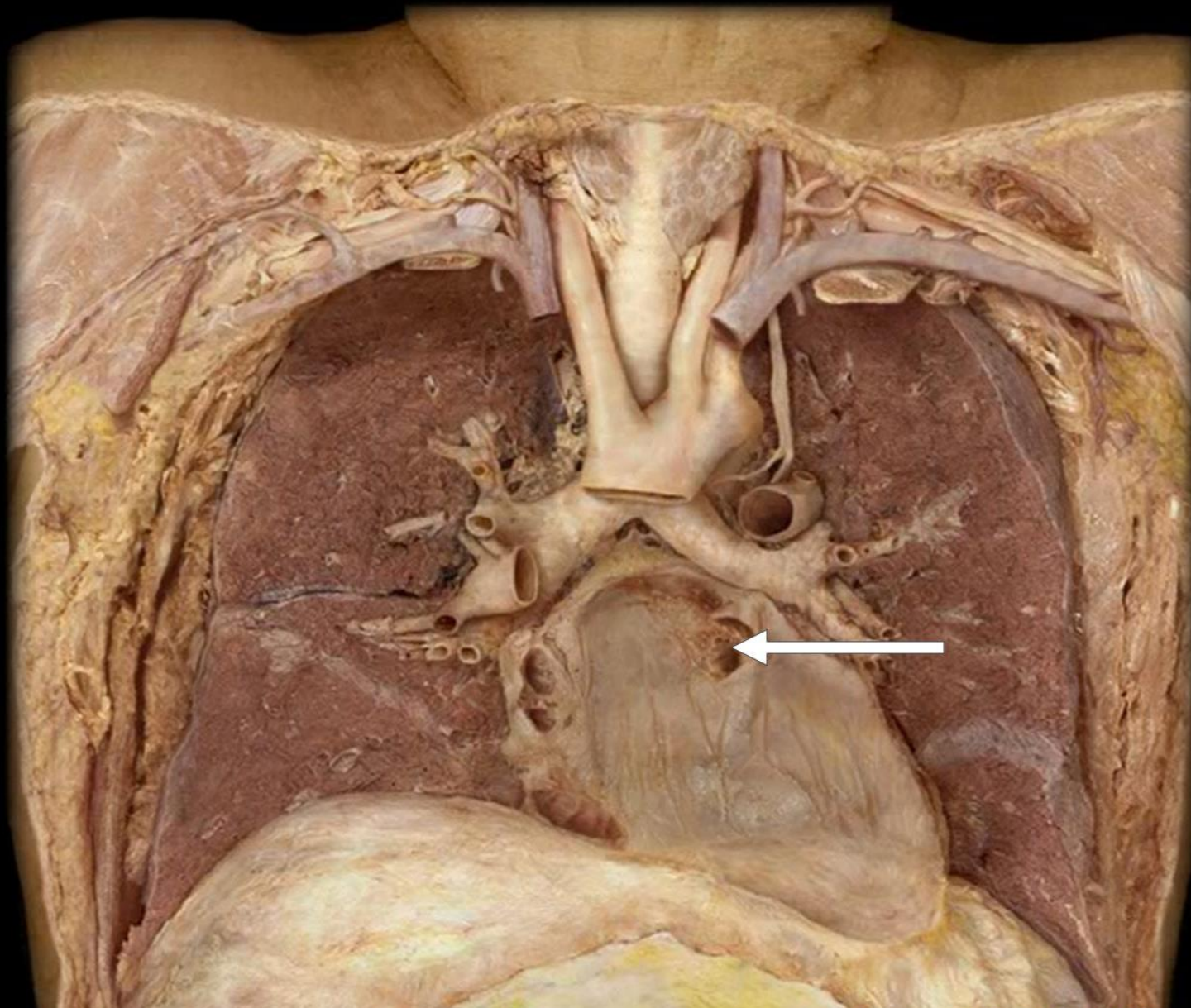
Right Pulmonary Artery



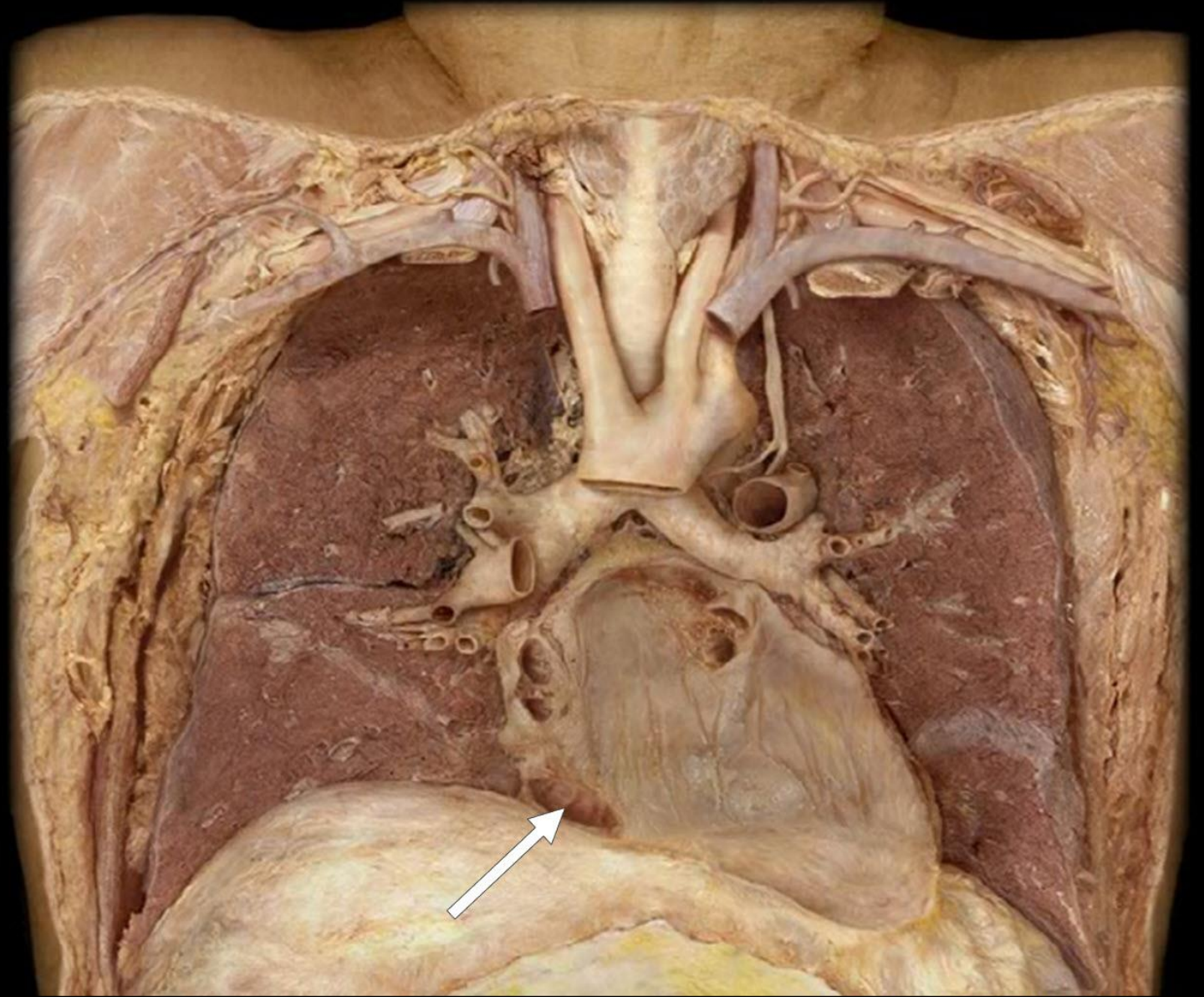
Two Right
Pulmonary Veins



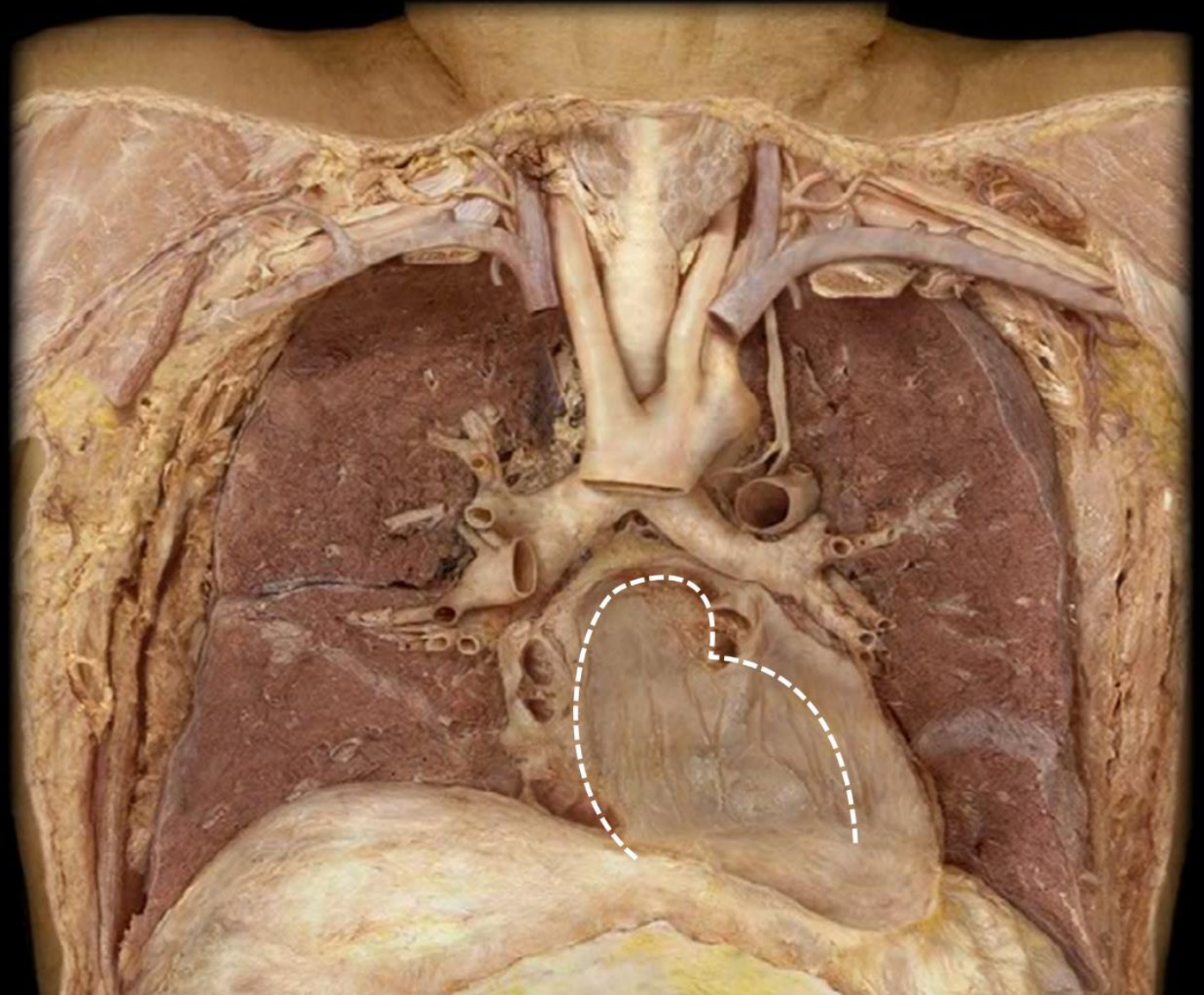
Two Left
Pulmonary Veins



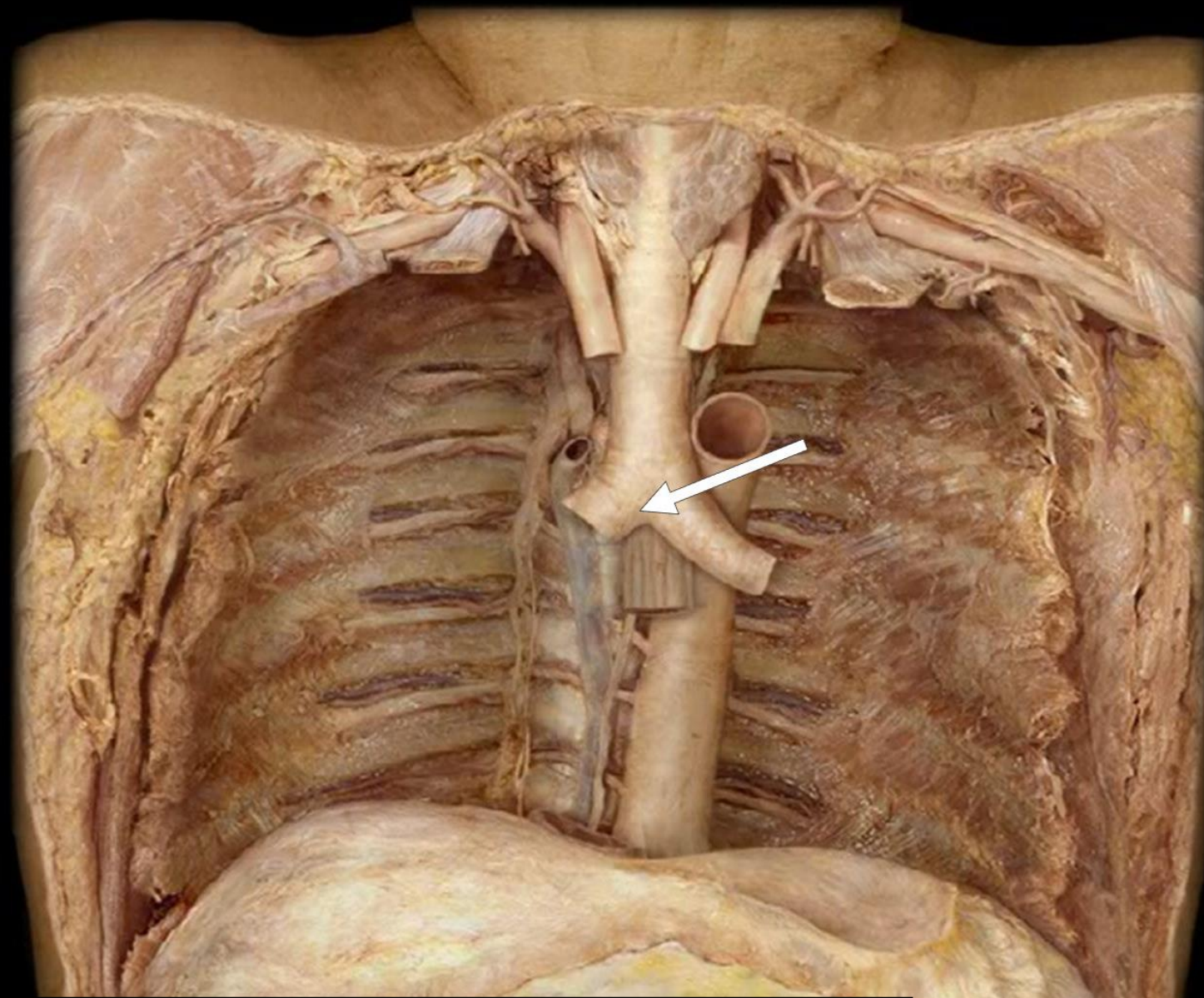
Inferior Vena Cava



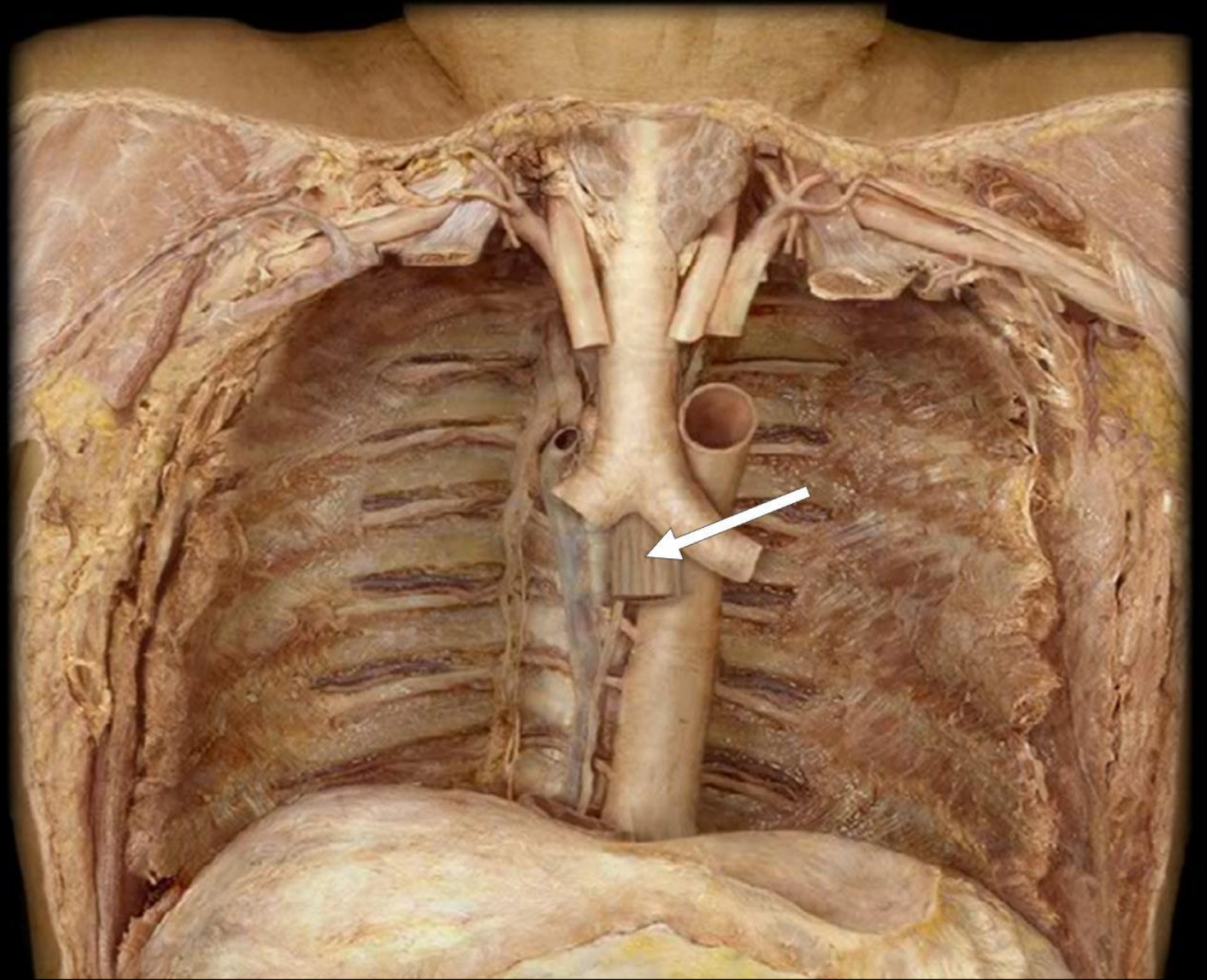
Oblique Sinus of Pericardium



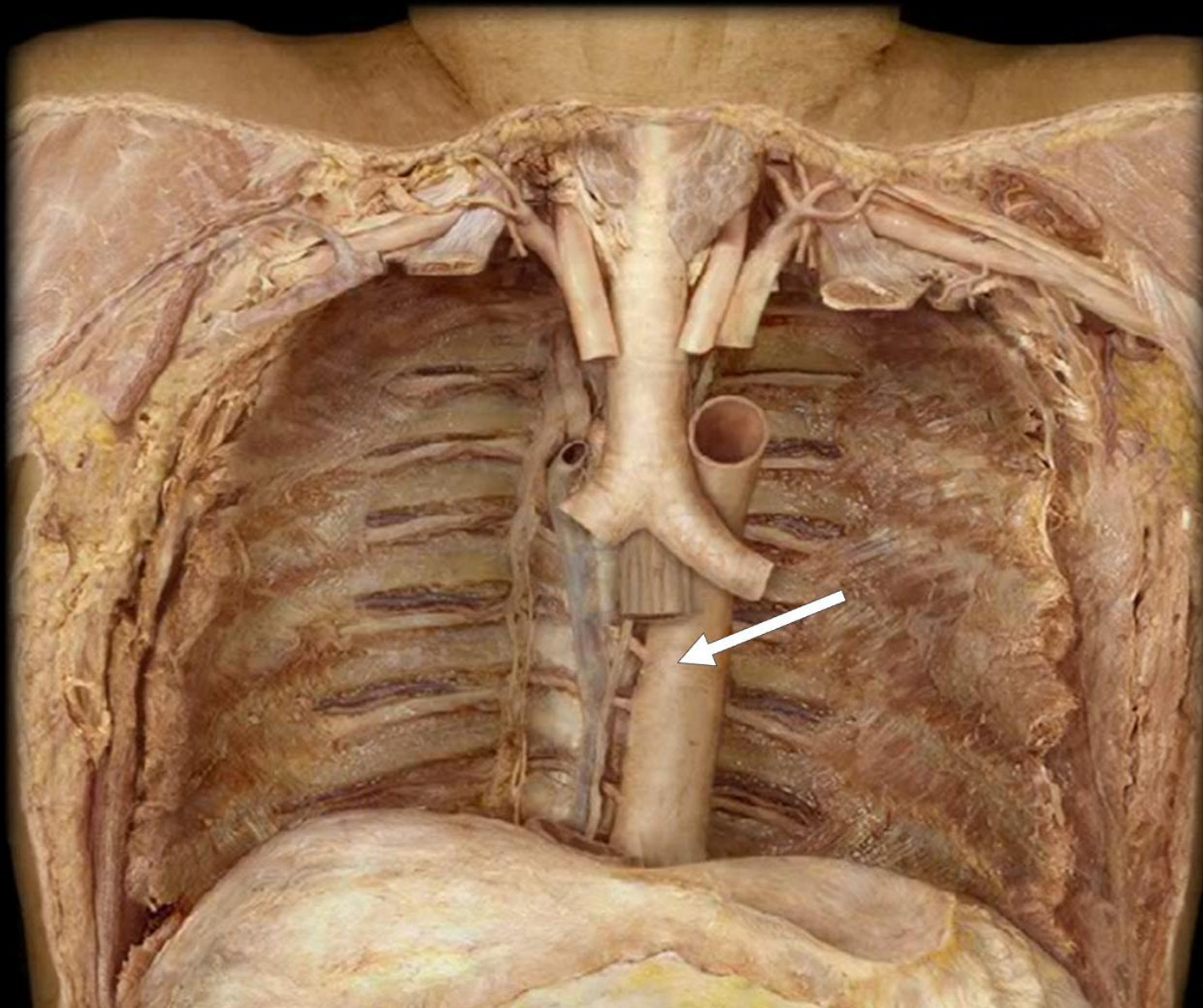
Bifurcation of Trachea



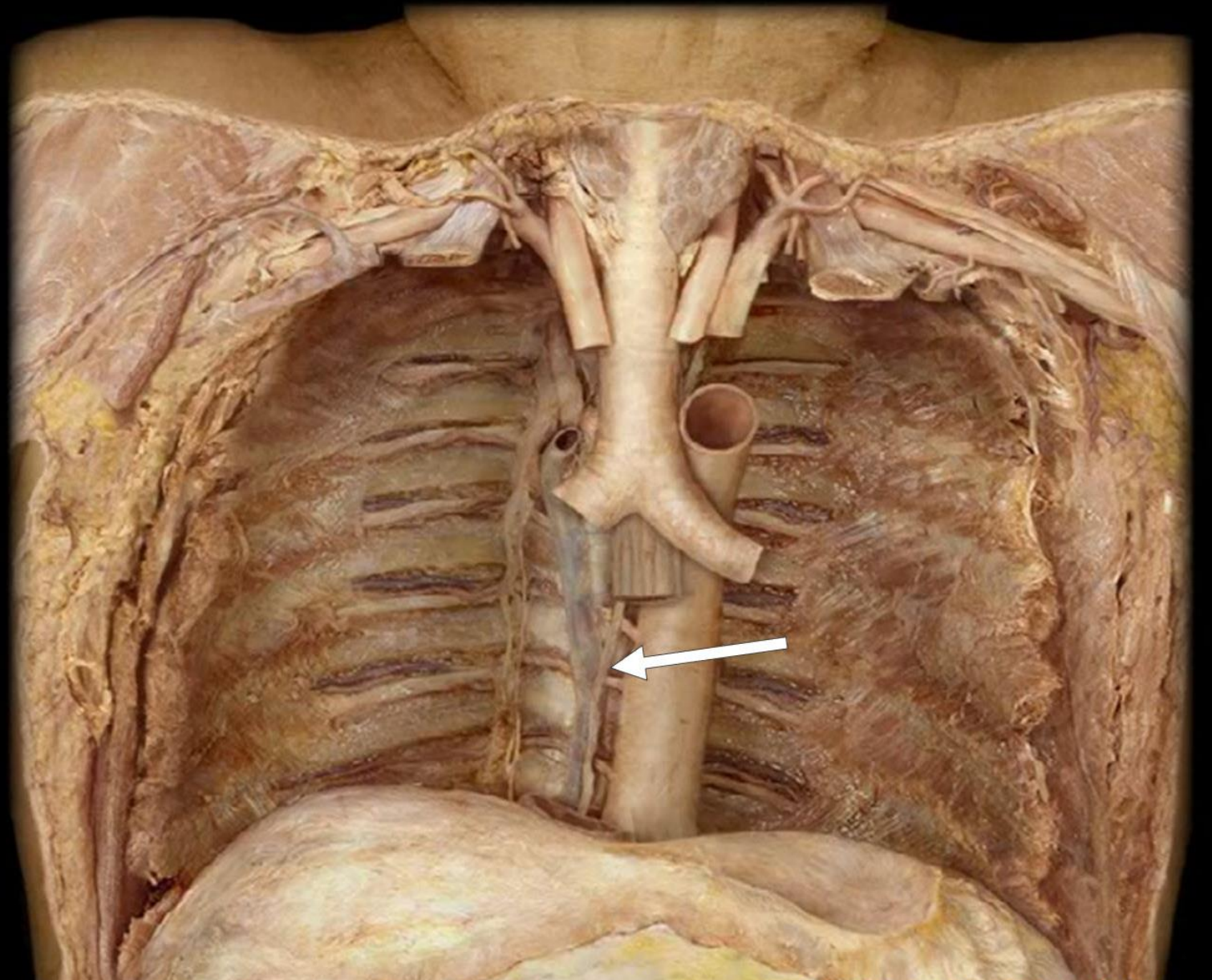
Esophagus



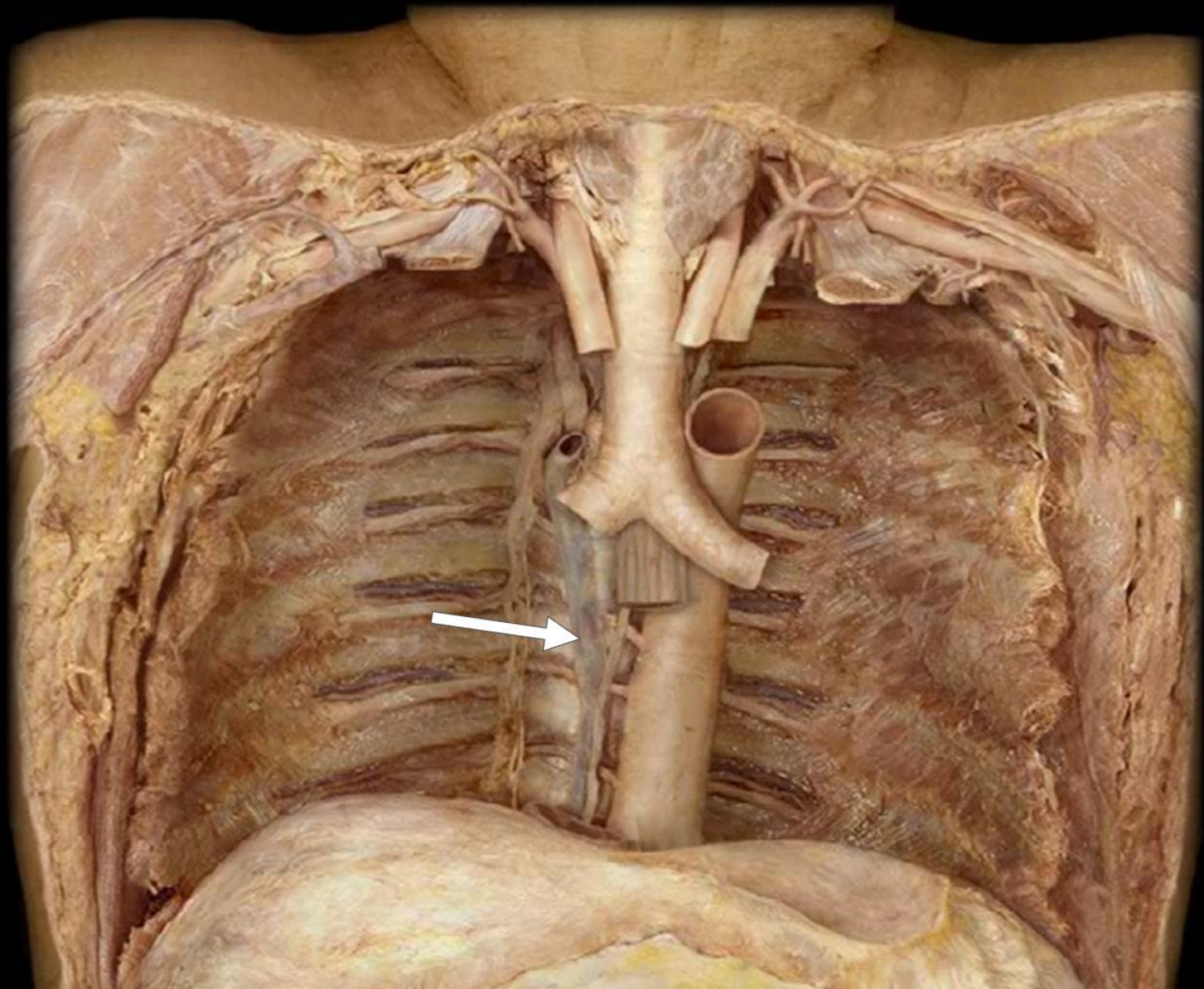
Descending Aorta



Thoracic Duct



Azygos Vein



Sympathetic Chain

